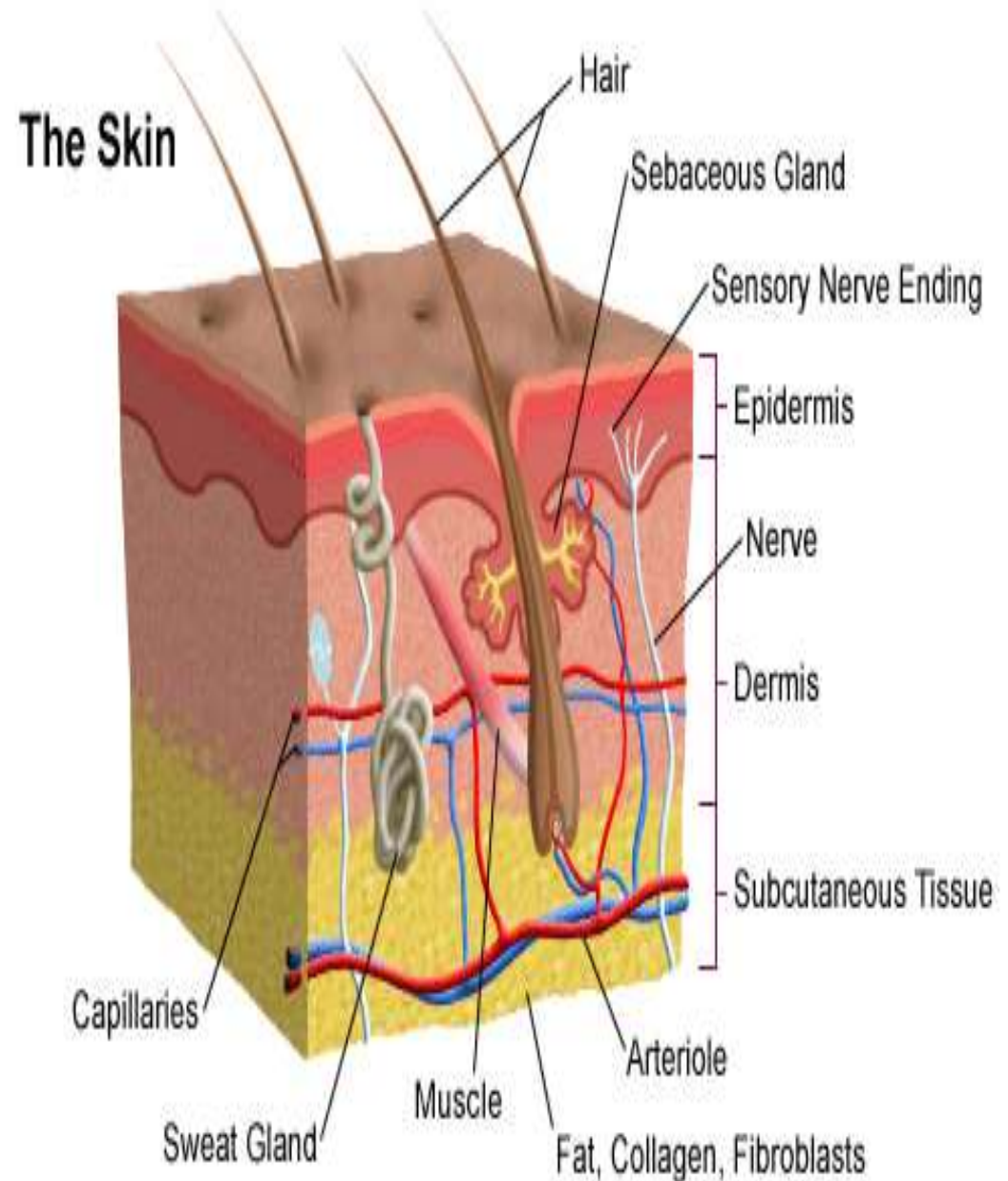


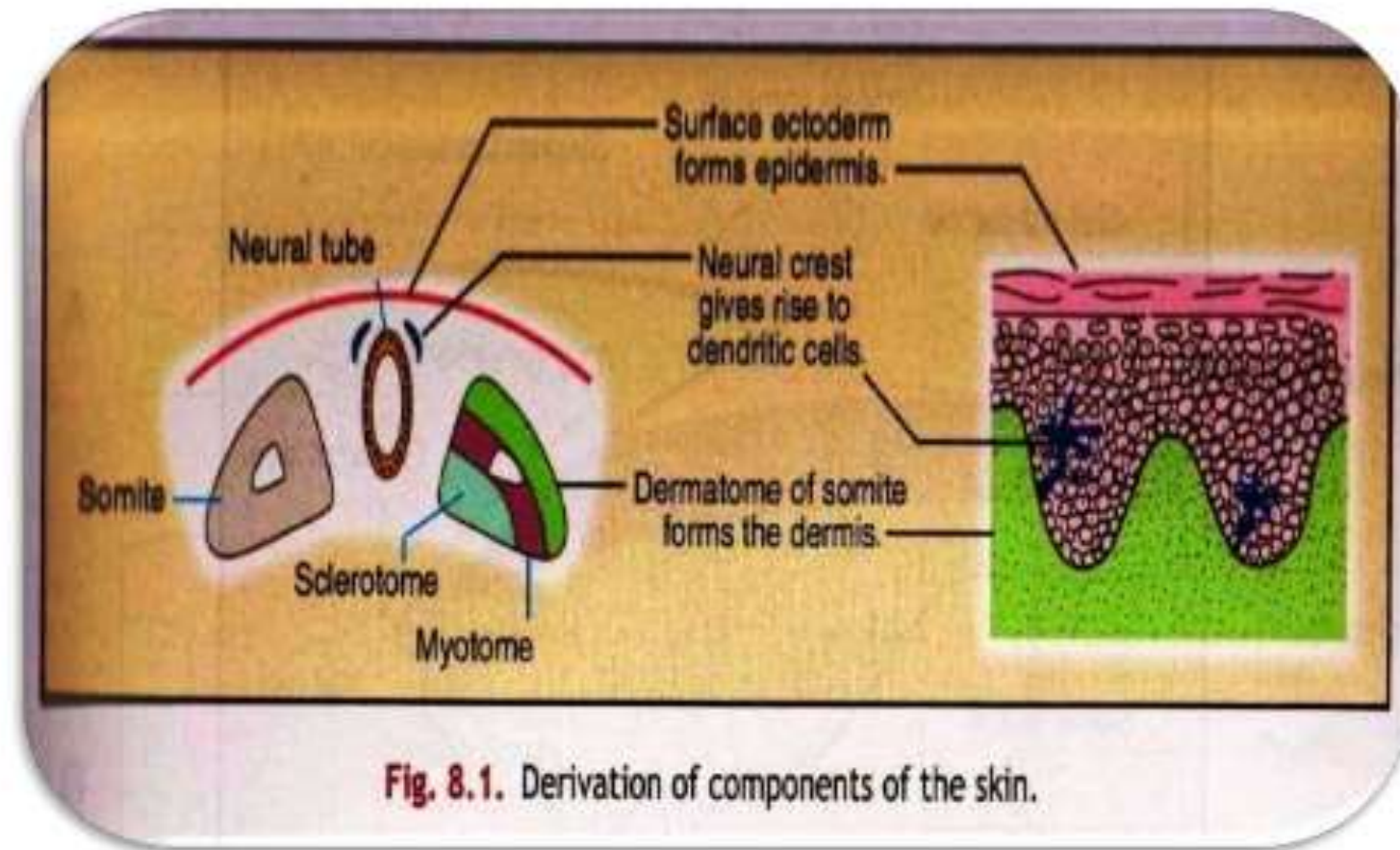
SKIN (cutis)

- Outer covering of body
- Continuous with **mucous membrane** in the region of
 - ✓ mouth
 - ✓ nose
 - ✓ urogenital organs
 - ✓ Anus
- Skin- 5% of TBM
- Skin + Subcutaneous tissue → **16- 18%**

- Largest sensory organ
- **THICKNESS-**
Thickest is on the Upper Back (**5mm**), thinnest on upper & lower eyelids (**<1mm**)



Embryology of skin



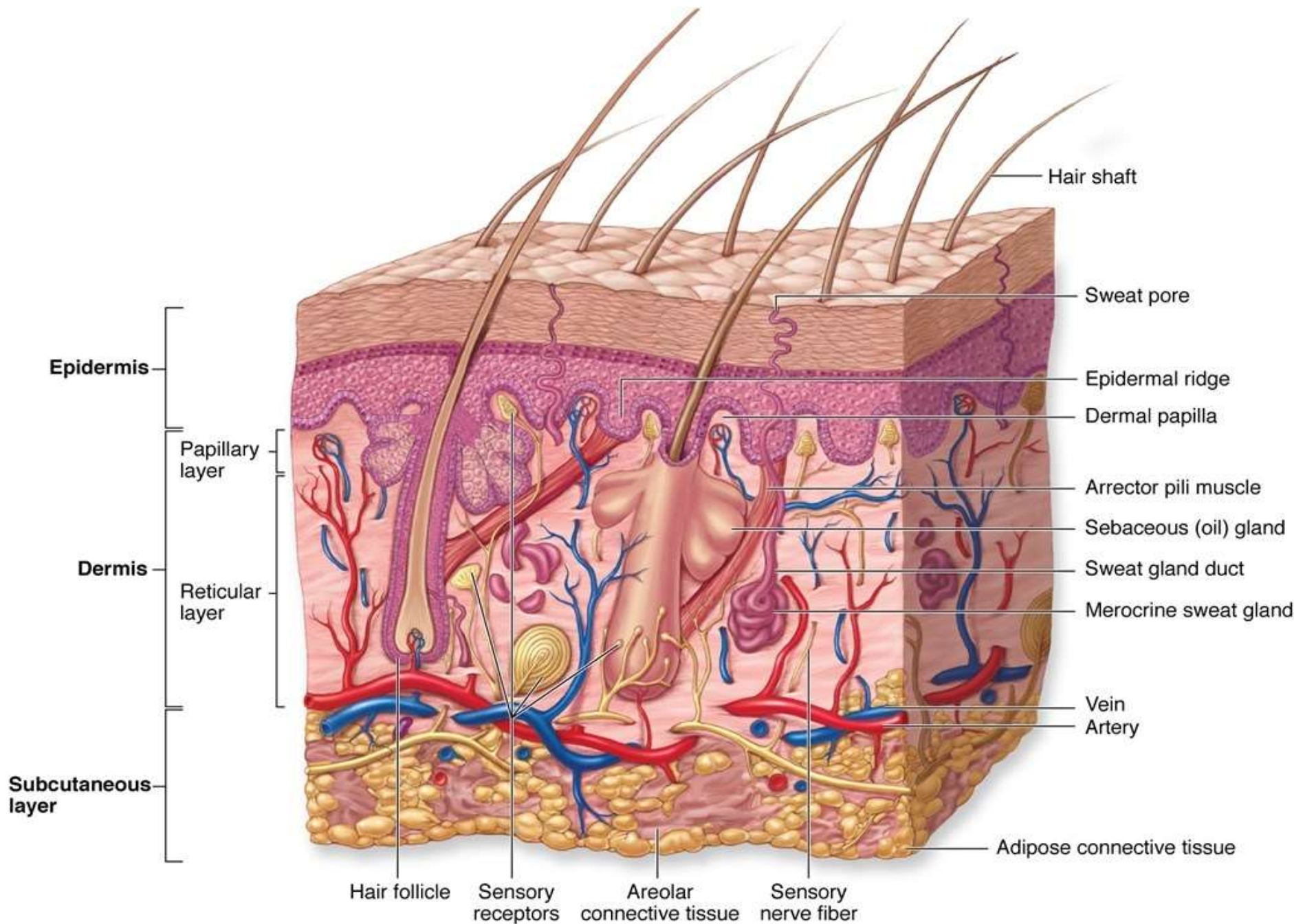
LAYERS OF SKIN

Epidermis

A diagram showing the three layers of skin. The top layer is a red rounded rectangle labeled 'Epidermis'. Below it is a purple rounded rectangle labeled 'Dermis'. The bottom layer is a green rounded rectangle labeled 'Hypodermis/ Subcutis'. Each layer is connected to a blue rectangular box on the right by a thin blue line. The boxes are stacked vertically, with the top box for the epidermis, the middle for the dermis, and the bottom for the hypodermis/subcutis.

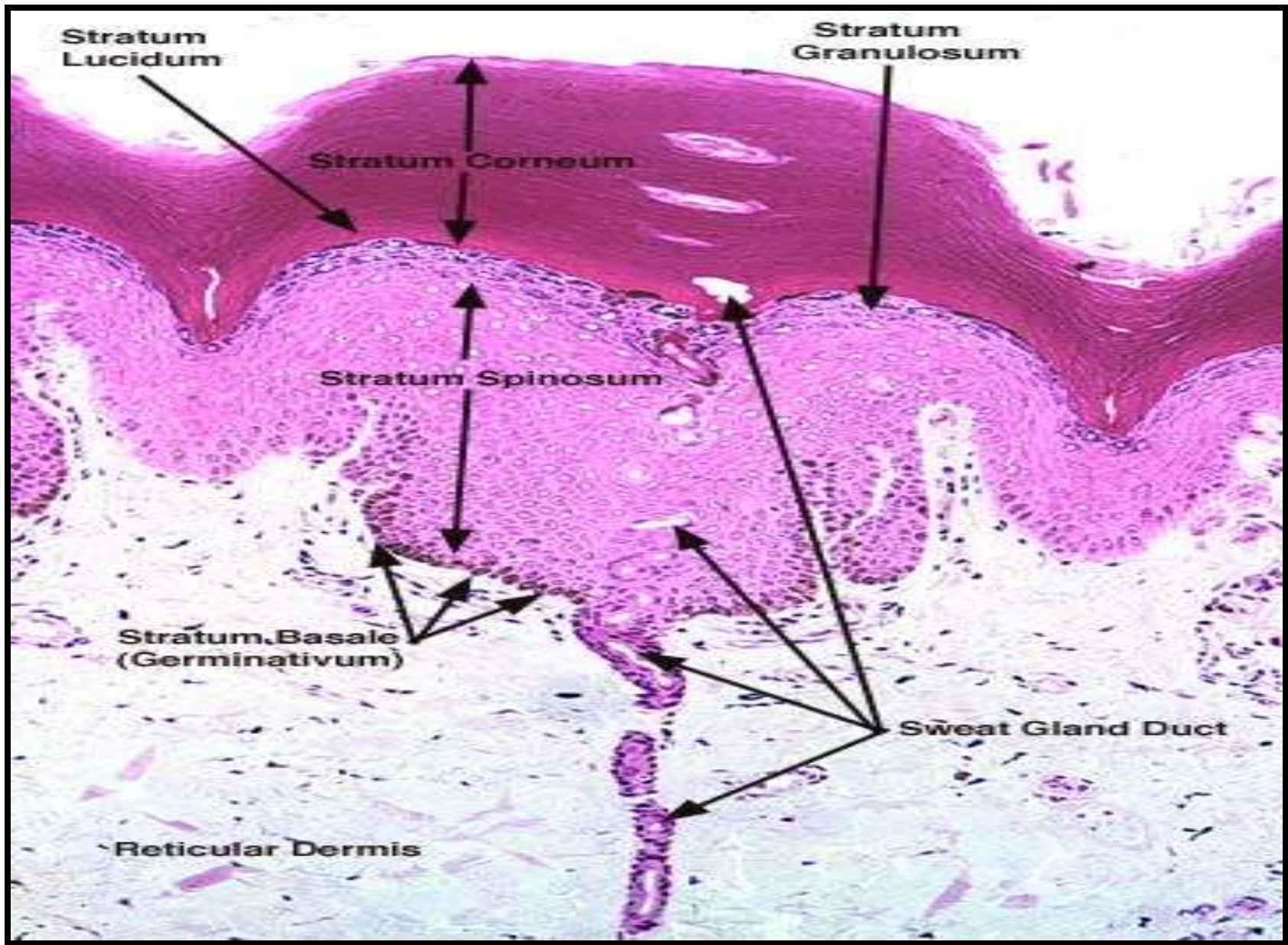
Dermis

Hypodermis/ Subcutis



EPIDERMIS

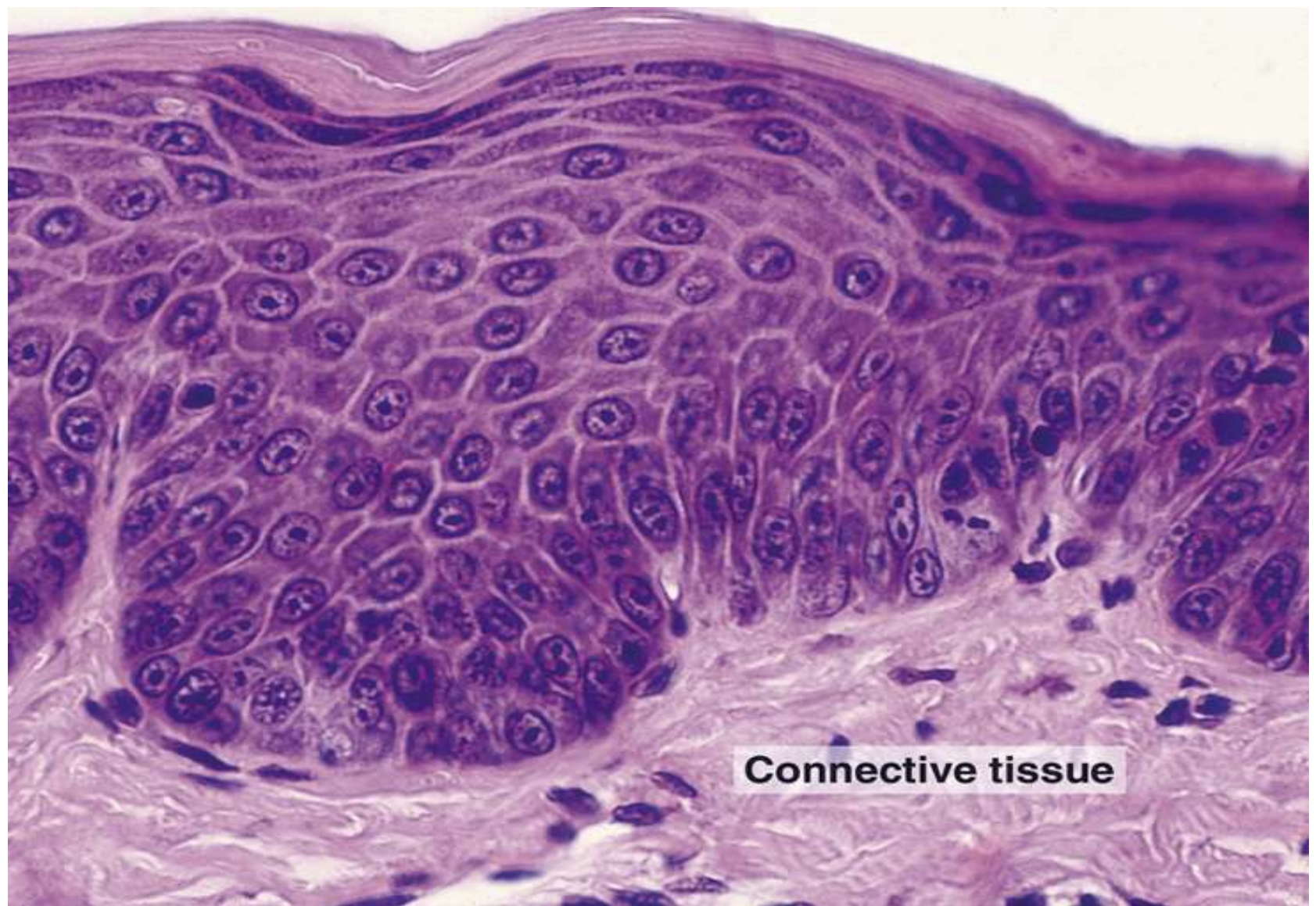- Cells of the Epidermis – **KERATINOCYTES**.
- Self regenerating Stratified Squamous Epithelium
- Outer protective layer of **KERATIN**
 - Stratum Basale
 - Stratum Spinosum
 - Stratum Granulosum
 - Stratum Lucidum
 - Stratum Corneum



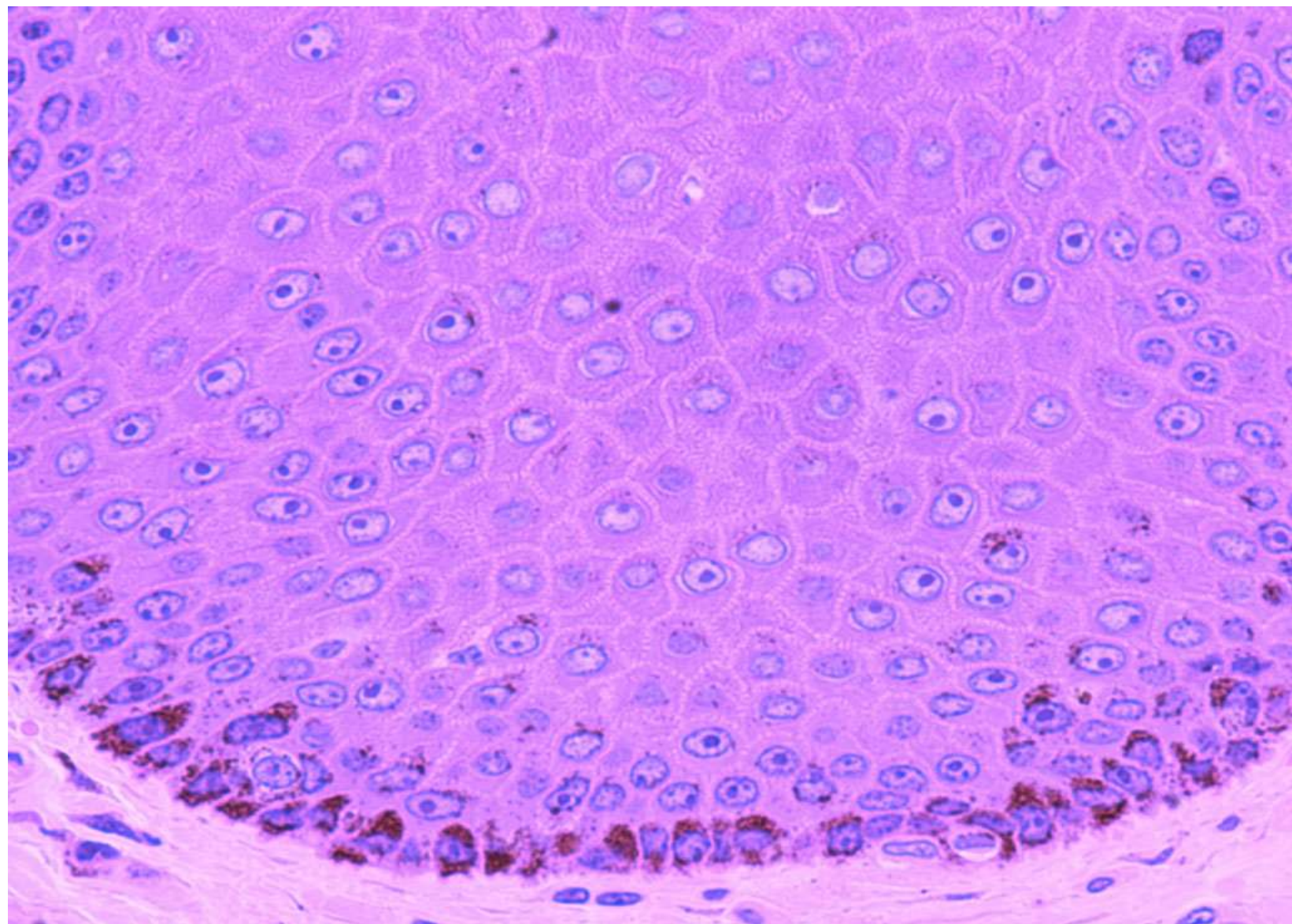
STRATUM BASALE

(GERMINATIVE LAYER OR STRATUM GERMINATIVUM)

- Basal layer of Epidermis, more **Basophilic cytoplasm**
- Proliferates continuously with repeated Mitotic division → gives rise to all other Keratinocytes
- Upward migration, Keratinocytes mature to form flattened cells.
- **Cuboidal or low Columnar cells**



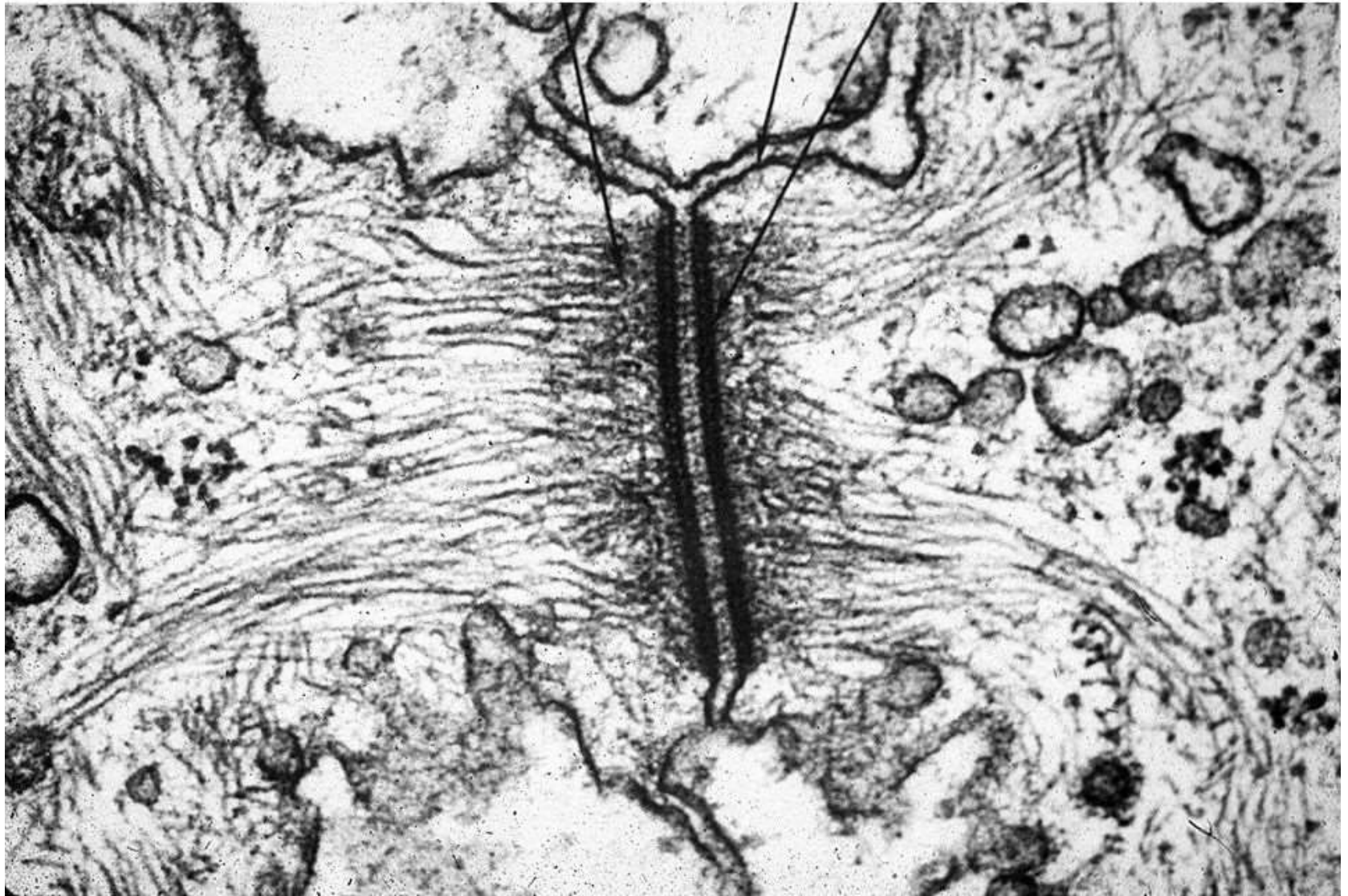
Connective tissue



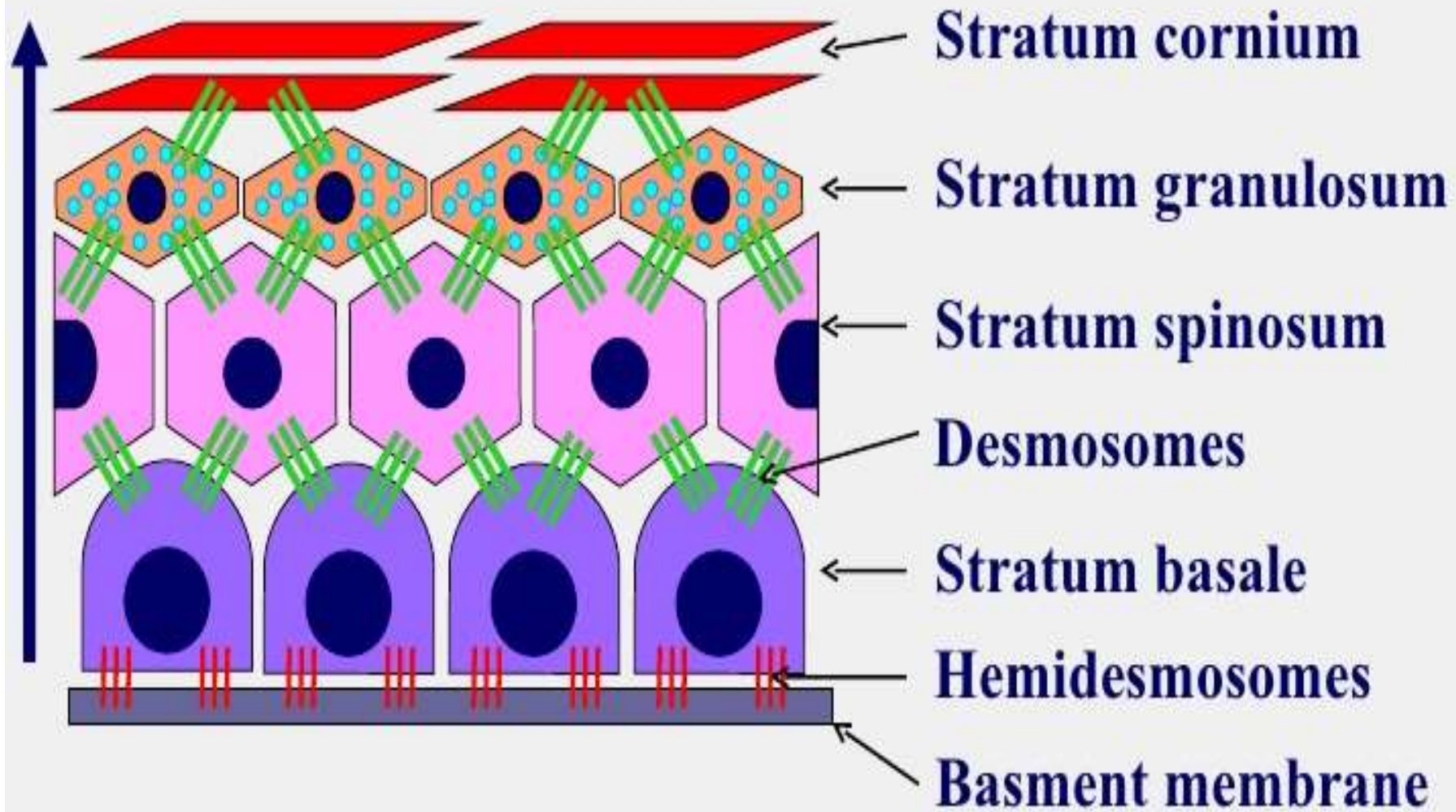
ELECTRON MICROSCOPY- Basal Layer

- Between these cells there are slit-like spaces called **intercellular bridges**.
- Basal surface – irregular, indented & folded with **Hemidesmosomes**.
- Cytokeratins accumulate in aggregates – **TONOFIBRILS** (EM)
- **HEMIDESMOSOMES**- Basal cells to the Basement membrane.
- **DESMOSOMES**- Basal cells linked to each other & prickle cells.

TEM of a Desmosome with tonofibrils

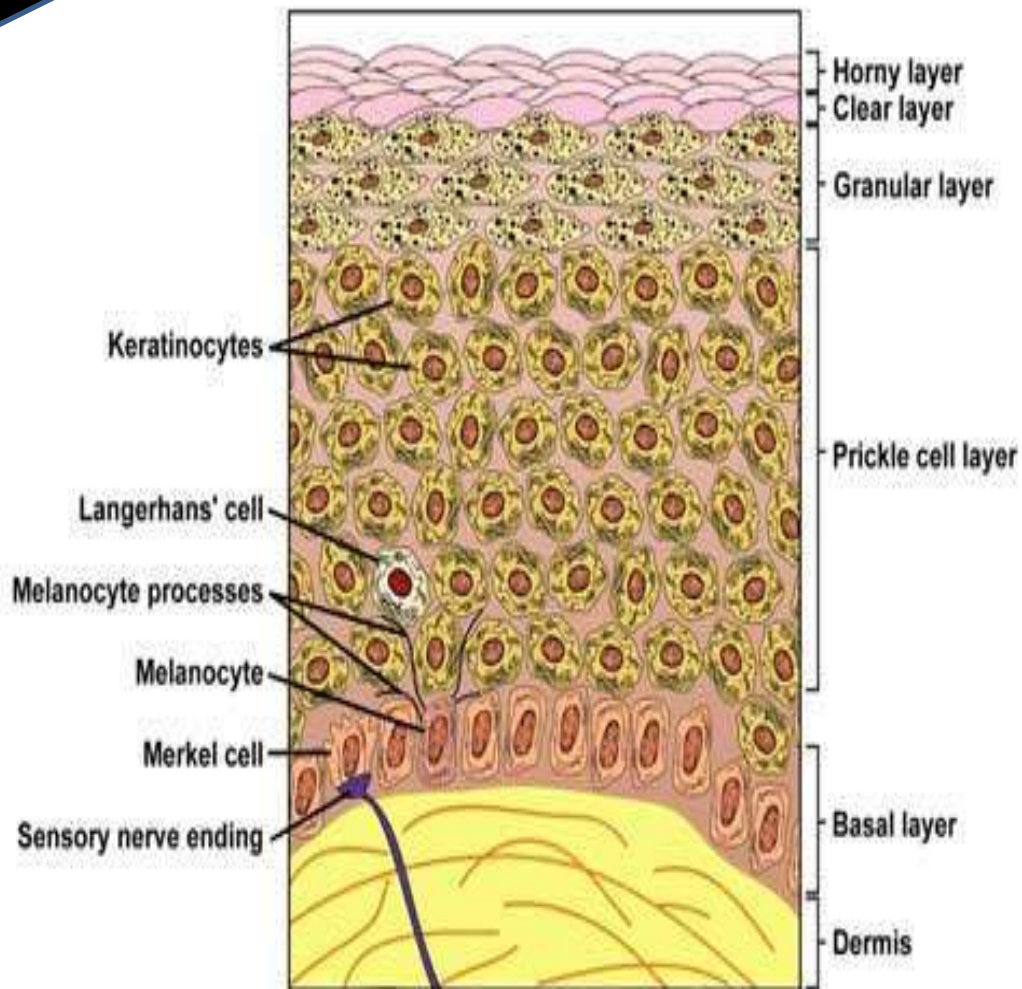
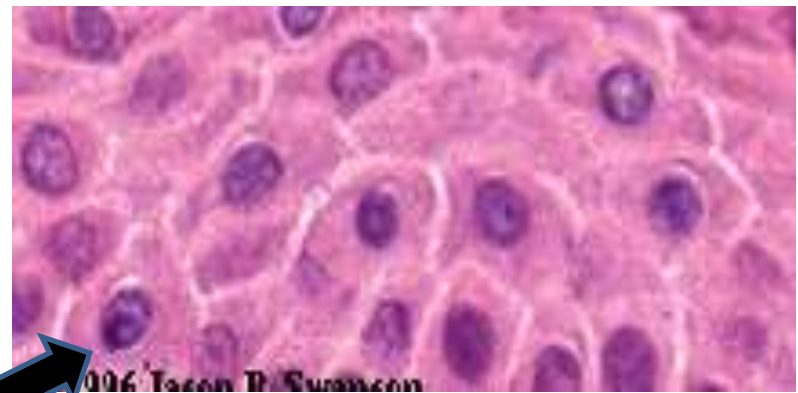
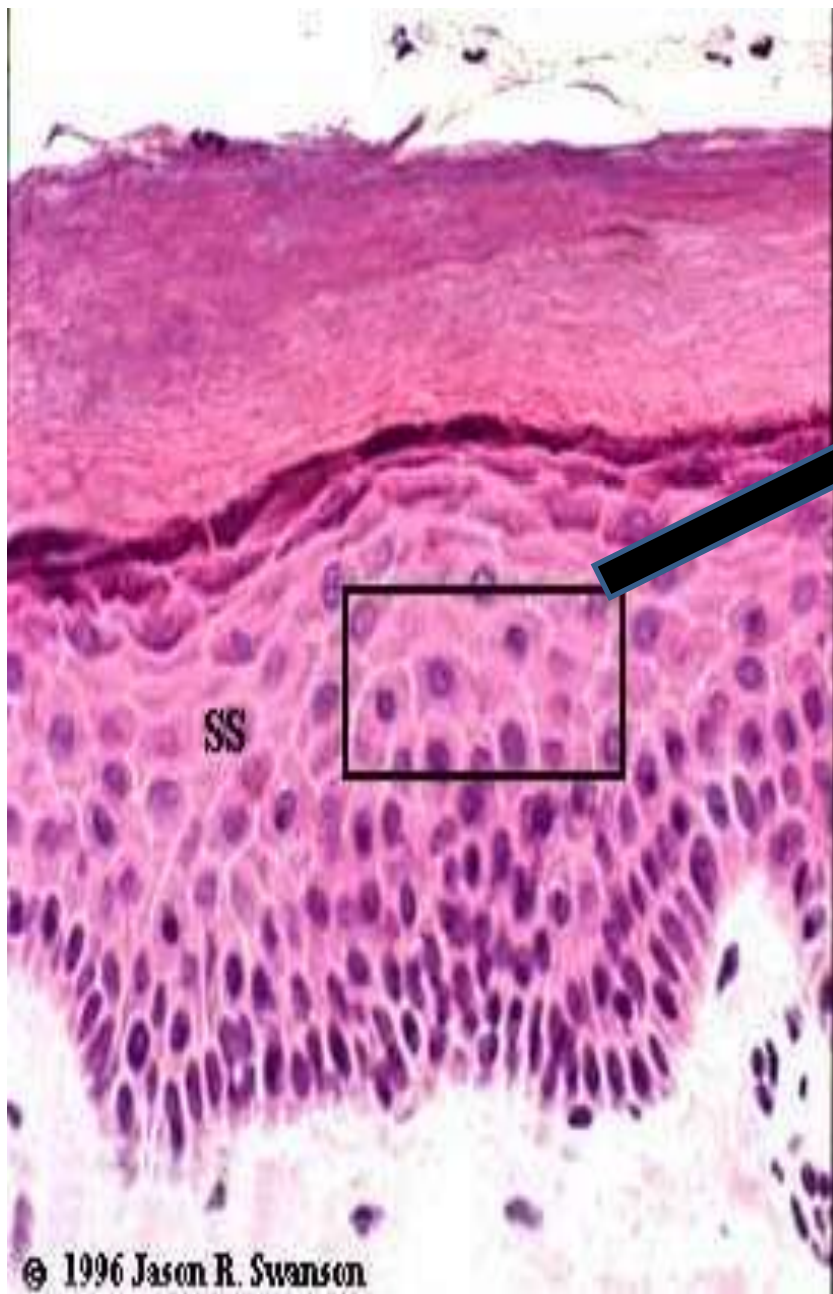


Epidermis



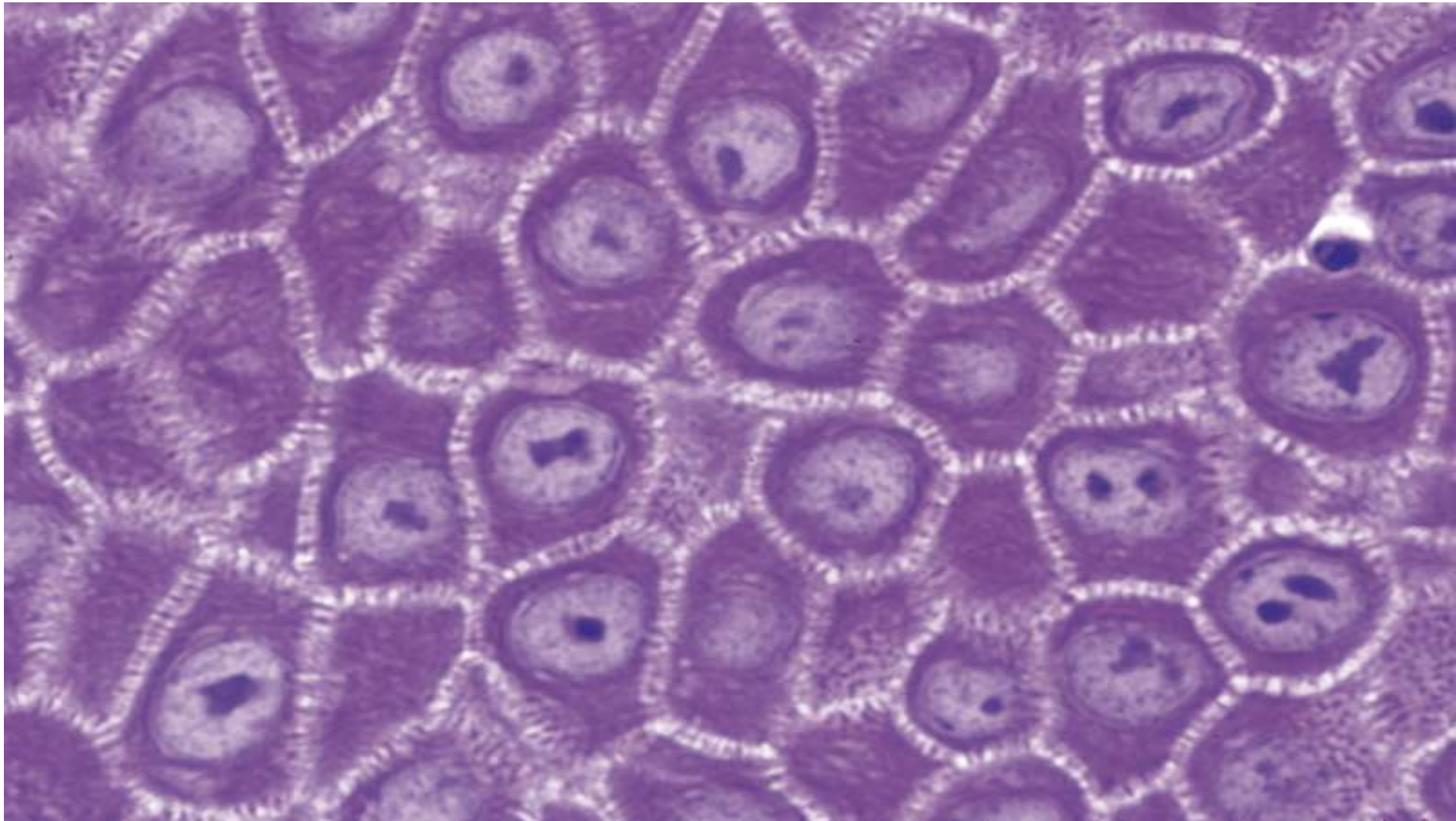
STRATUM SPINOSUM (PRICKLE CELL LAYER)

- Majority of the Epidermis, Multi-layered
- **Polyhedral** shaped keratinocytes, round – oval nuclei, prominent nucleoli & cytoplasm.
- **Pavement like pattern**
- Synthesizes Cytokeratins- Cytoplasmic intermediate filaments.



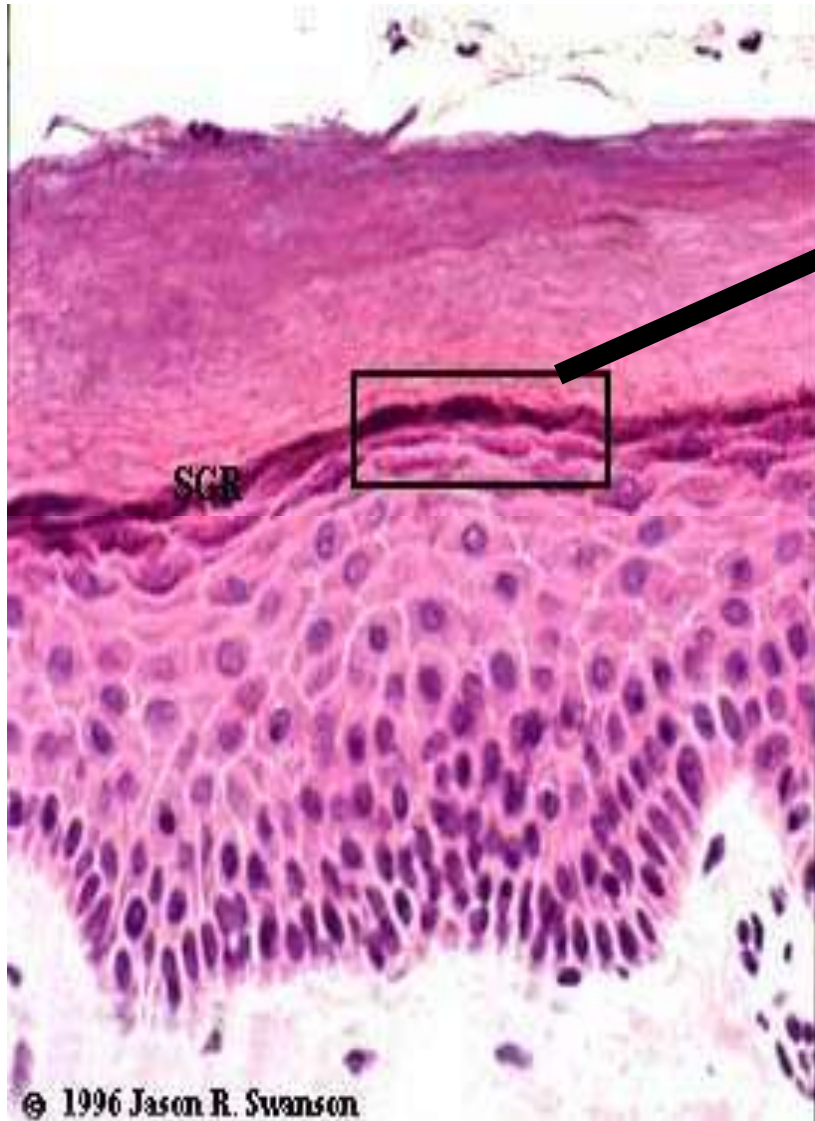
PRICKLE CELL LAYER

- Desmosome junctions are seen as **Sprinkles** or **Spines** between the cells, hence the name.

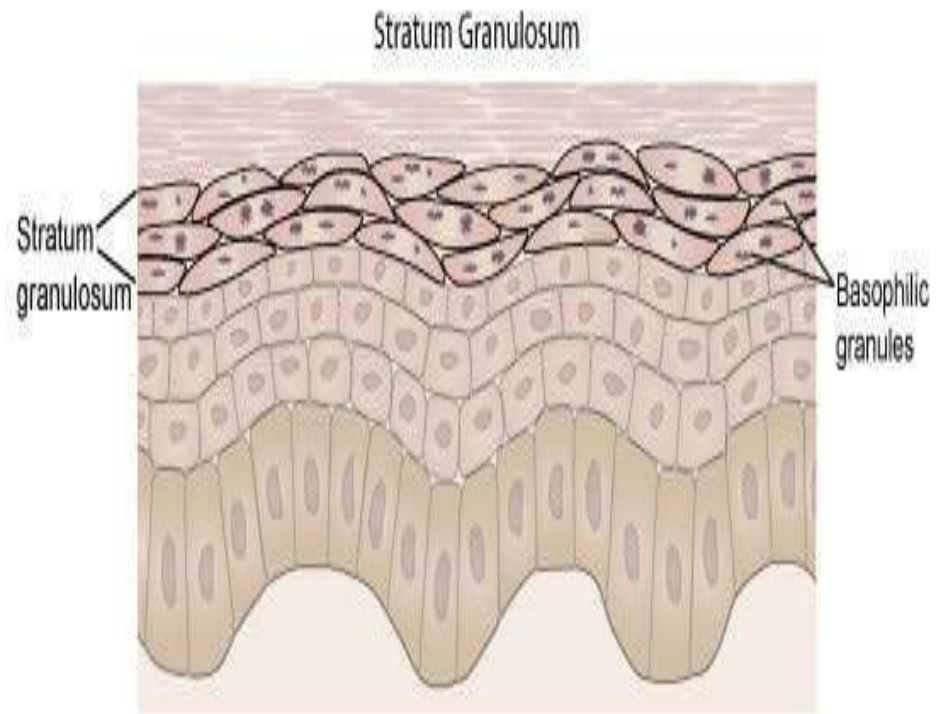
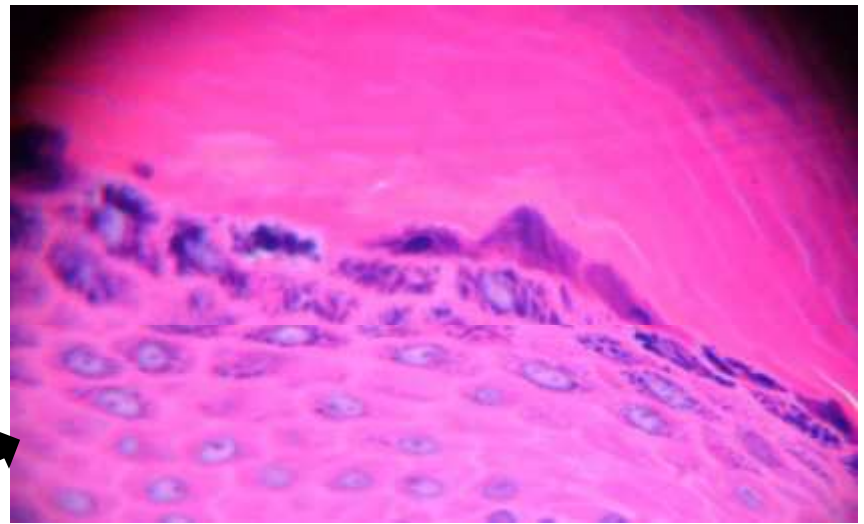


STRATUM GRANULOSUM

- Keratinocytes mature into Stratum Granulosum
- **KERATOHYALINE GRANULES**- in cytoplasm – dense, ovoid, basophilic
- ✓ contains proteins, rich in **Sulphur** containing Amino acids CYSTEINE & HISTIDINE
- ✓ proteins – **INVOLUCRIN** which interact with Cytokeratin Tonofibrils in the final maturation
- ✓ Represent precursor of protein **FILAGGRIN** (resp for Aggregations of keratin filaments)



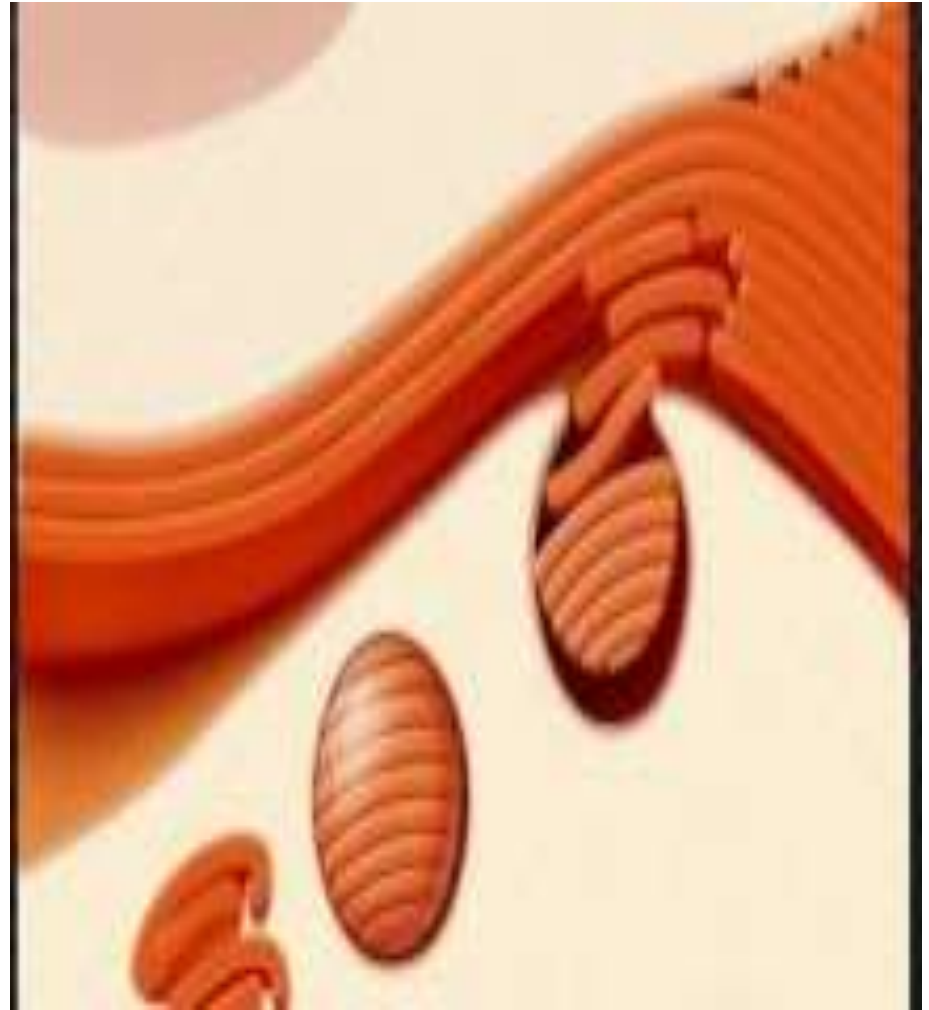
© 1996 Jason R. Swanson



(c) 2007 Heather Brannon, MD licensed to About.com, Inc

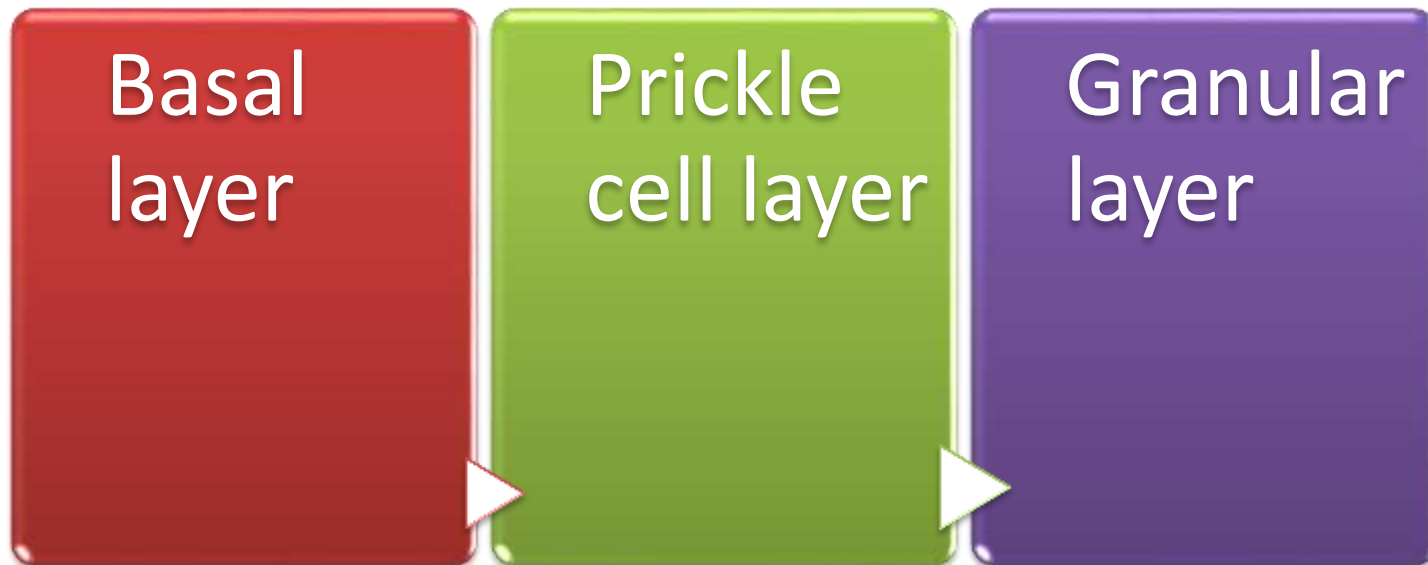
- **KERATINISATION**- Combination of Tonofibrils with Keratohyaline granules produces Keratin.
- KERATINISATION CYCLE – **30-45 days**
- **ODLAND BODIES**- Lamellated pale staining ovoid bodies.
- ✓ Hydrophobic glycolipid which when released coats & binds together the Keratin flakes, rendering them relatively water repellent.

ODLANDBODIES



STRATUM MALPIGHII

- Rete Malpighii

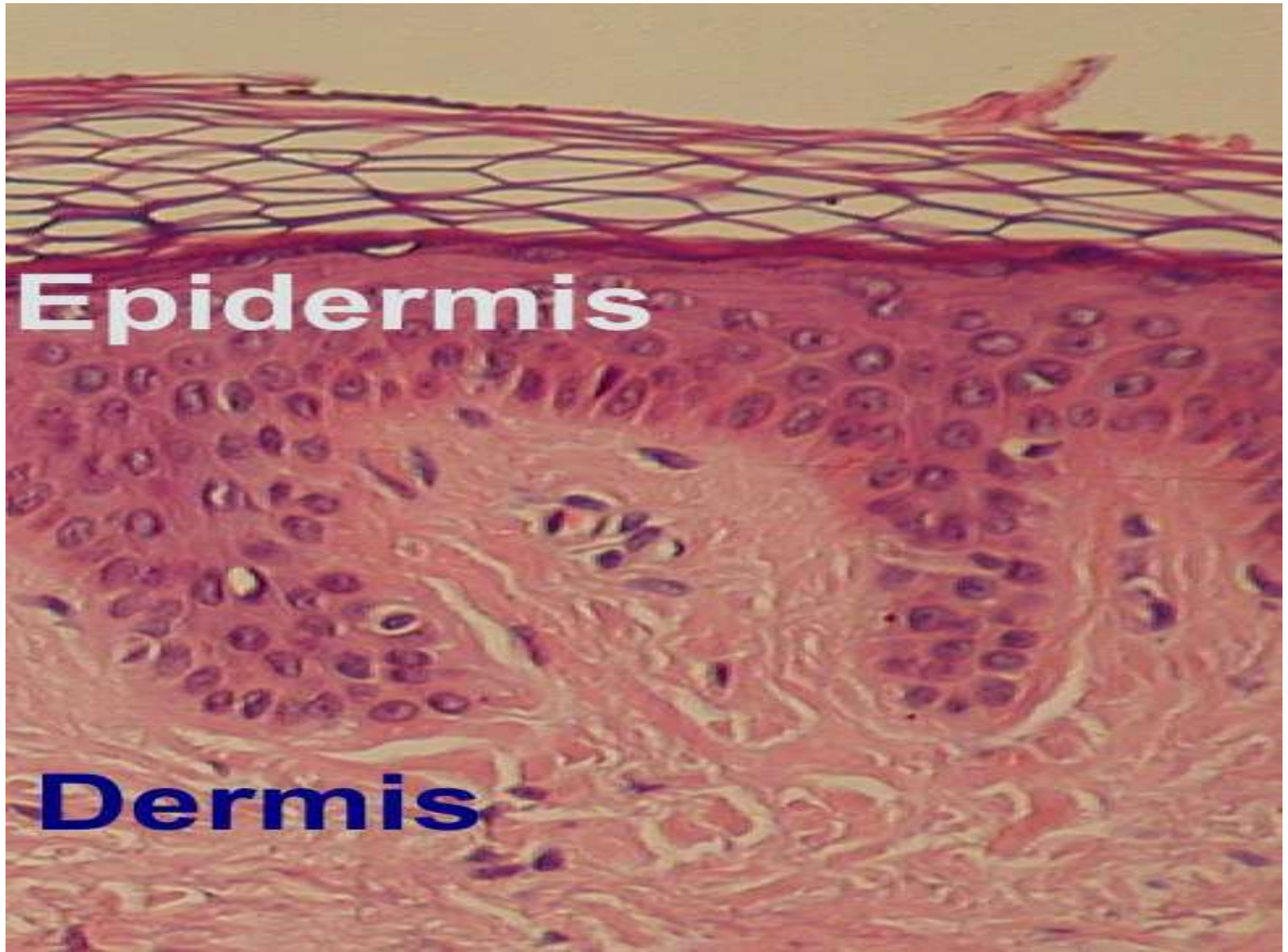


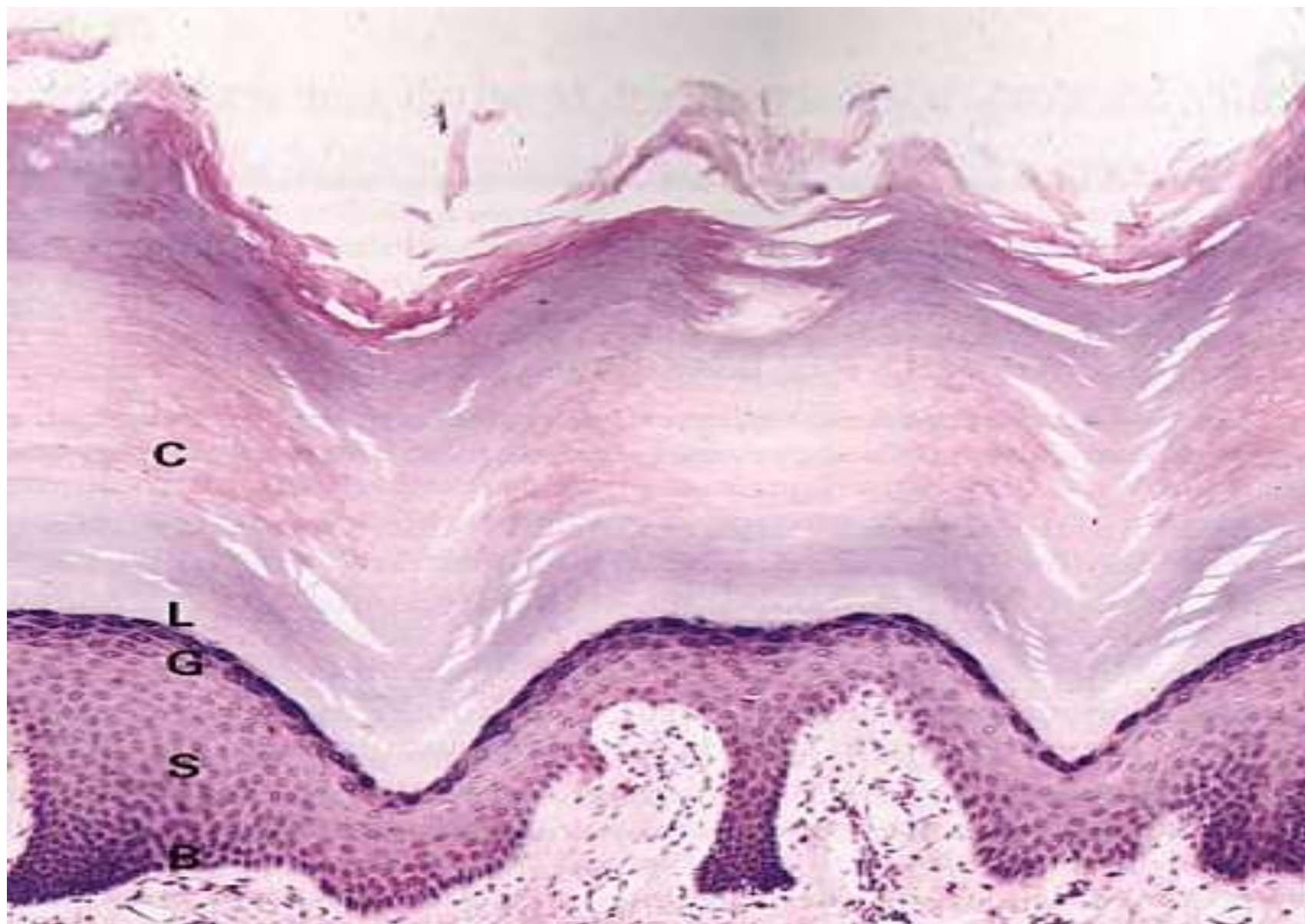
STRATUM CORNEUM

- Anucleate
- **KERATIN SQUAMES**- Lose their nuclei → flattened
- **ORTHOKERATOSIS**- Keratin Squames connect at their edges → folded Basket weave pattern. Except in Acral region (thick & compact)
- Thickness- difficult to ascertain in formalin fixed specimen- some of the outer cell layers frequently detach themselves

STRATUM CORNEUM

- **BASKET WEAVE PATTERN**- Large intercellular spaces





- **HYPERKERATOSIS:**

- Thickening** of the Stratum Corneum, often associated with qualitative abnormality of Keratin

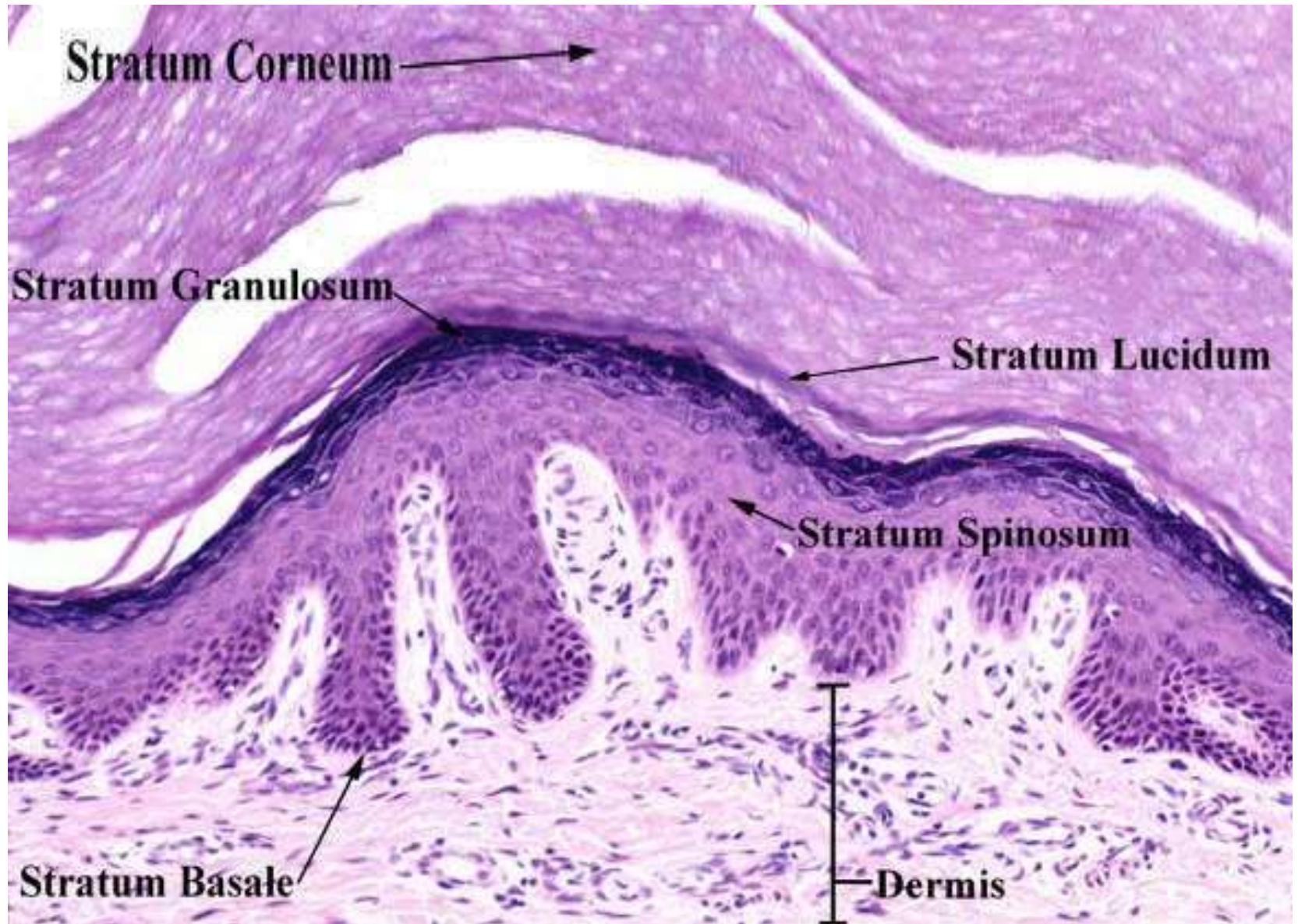
- **PARAKERATOSIS:**

- Keratinisation with **retained nuclei** in the Stratum Corneum.

STRATUM LUCIDUM

- Between the Granular & Cornified layers
- Skin from the **Palms & Soles**
- Difficult to identify in H&E sections
- Thin Homogenous eosinophilic zone

STRATUM LUCIDUM



DERMO- EPIDERMAL JUNCTION

- Basement Membrane at the junction of Epidermis & Dermis
- Folds of interlocking ridges of epidermis **RETE RIDGES** and **DERMAL PAPILLAE**

Meissner's
corpuscle

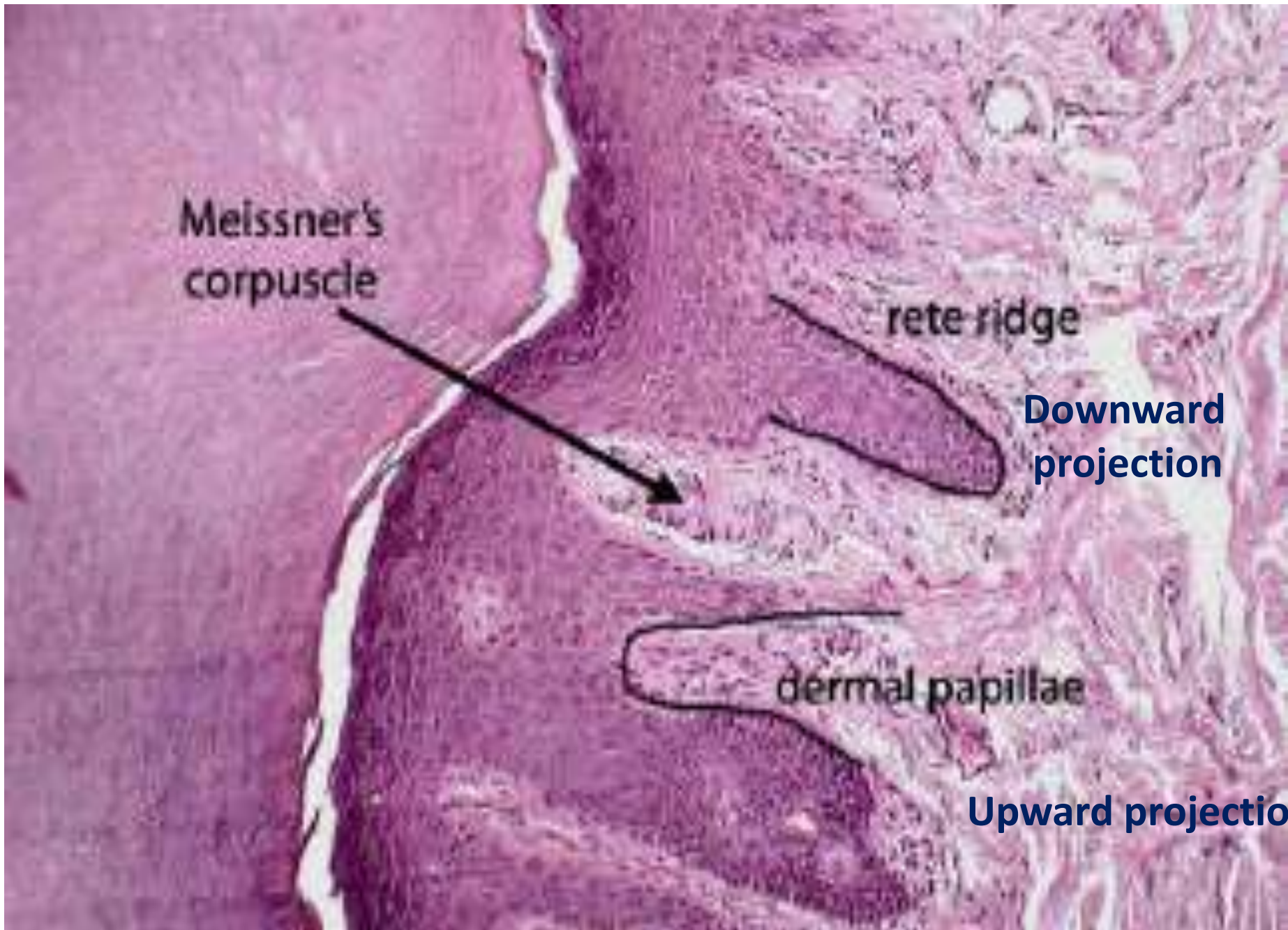


rete ridge

Downward
projection

dermal papillae

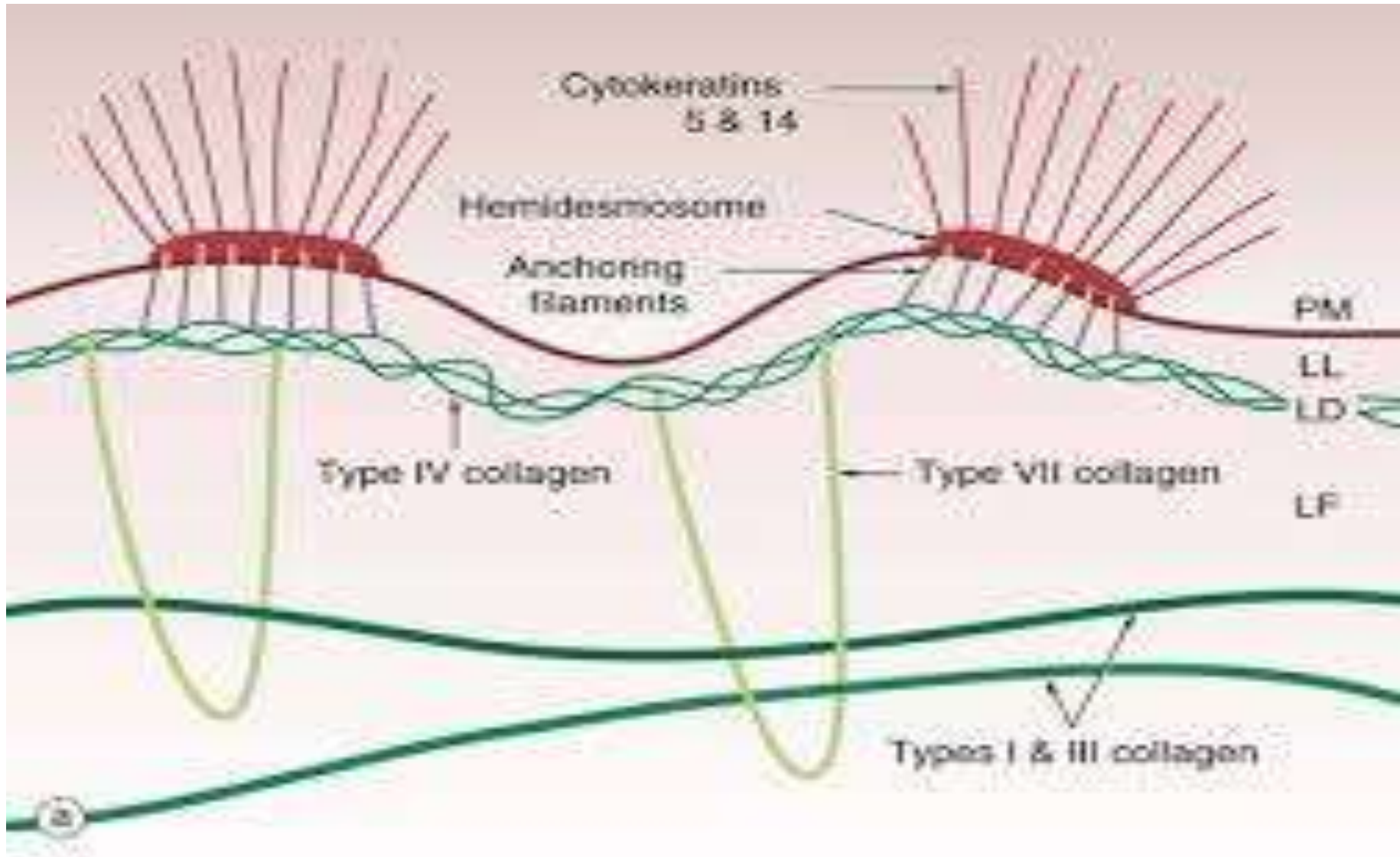
Upward projection



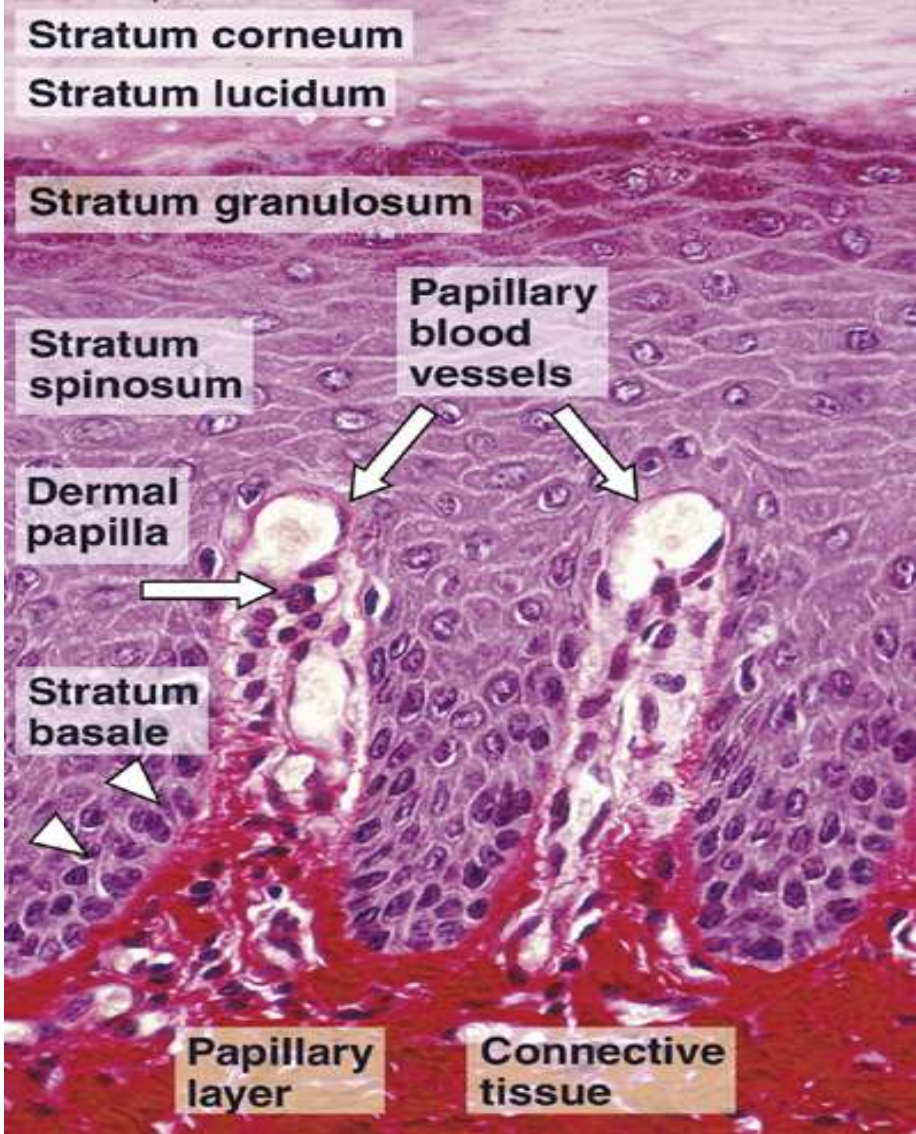
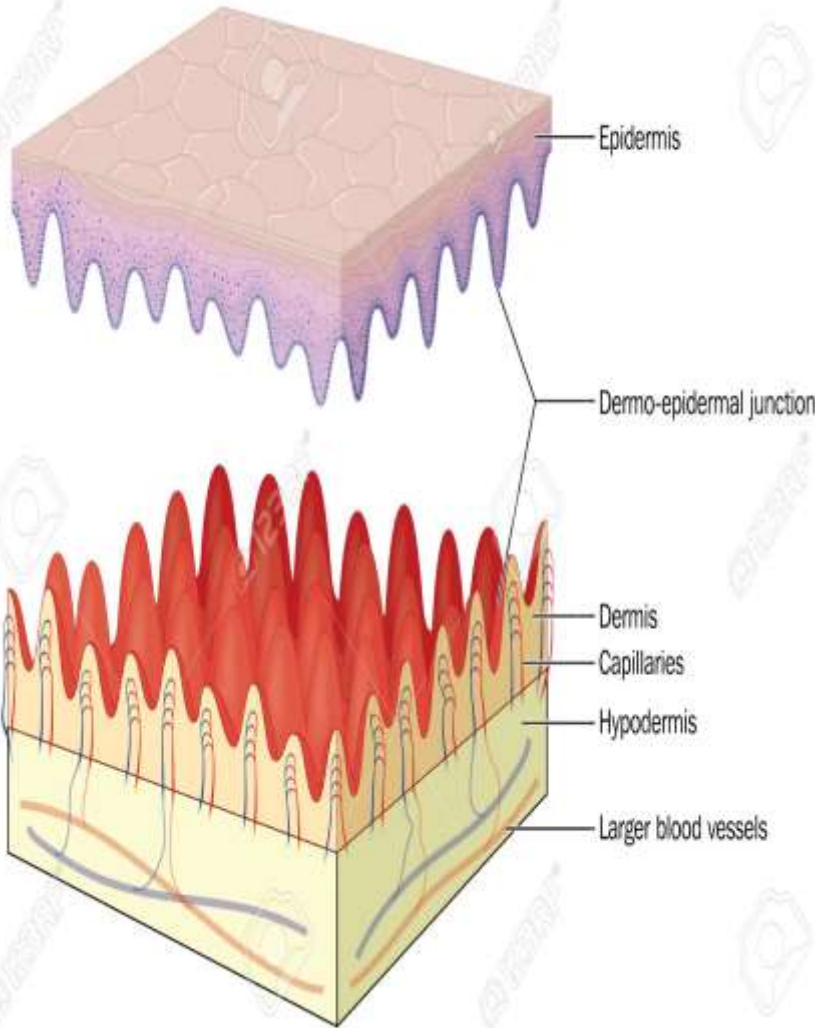
DERMO- EPIDERMAL JUNCTION

- Cytoplasmic Tonofibrils- CYTOKERATINS 5 & 14 binds to Hemidesmosomes. – TYPE 7
Collagen fibres & INTEGRINS.
- **Anchoring Filaments-** NIDOGEN 1 & LAMININS
- **LAMINA LUCIDA-** electron translucent layer, most easily disrupted of the Basement membrane layer
- **LAMINA DENSA-** electron dense layer. Type 4 collagen -mesh forming basement memb

DERMO- EPIDERMAL JUNCTION



DERMO EPIDERMAL JUNCTION

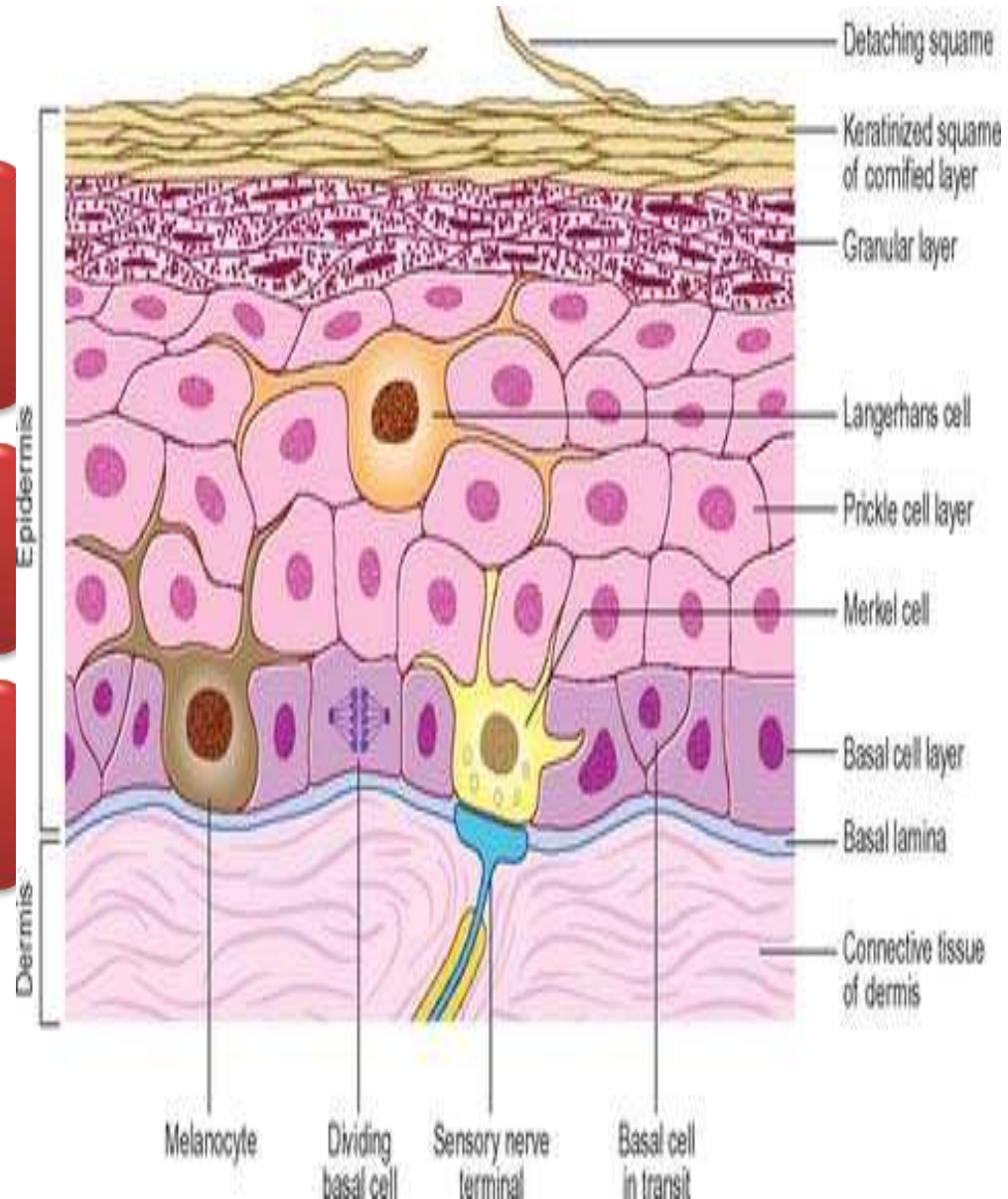


SPECIALISED CELLS IN EPIDERMIS

Melanocytes

Langerhan cells

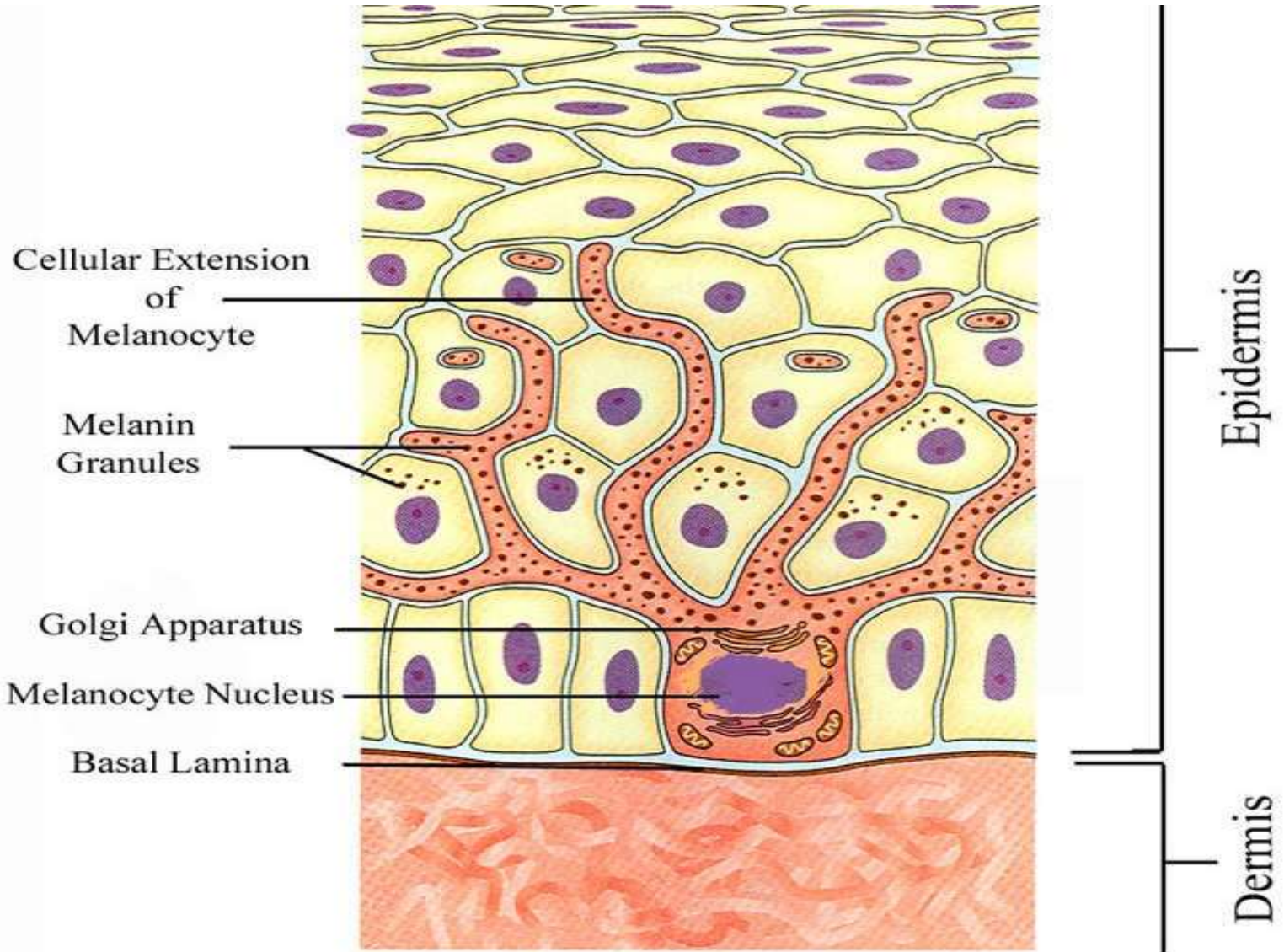
Merkel cells



MELANOCYTES

- Neural crest derived cells
- Basal layer of epidermis- between two Basal Keratinocytes
- Rounded cell bodies, clear cytoplasm=
MASSON CLEAR CELLS
- Slender cytoplasmic processes (**Dendrites**)

MELANOCYTES



Location of Melanocytes

- Basal layer of Skin
- Hair follicles
- Most Squamous covered Mucosal membranes
- Leptomeninges

MELANIN- yellowish brown to black

Tyrosine

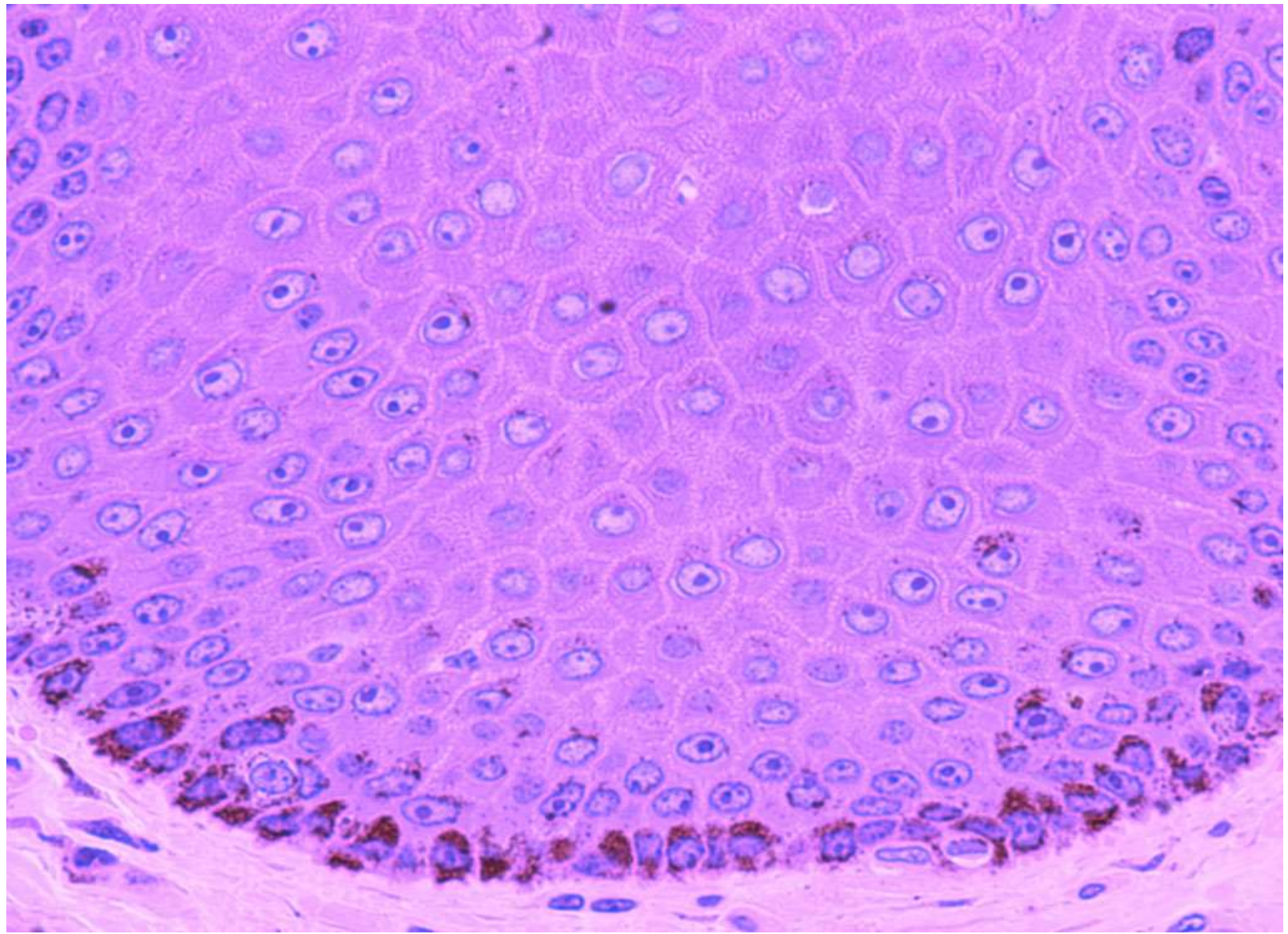
```
graph TD; Tyrosine --> DOPA; DOPA --> Melanin; Melanin --> Melanoprotein;
```

The diagram illustrates the synthesis of melanin. It consists of four horizontal bars, each containing a name, arranged in a descending staircase pattern from top-left to bottom-right. The bars are: 1. Tyrosine (green), 2. DOPA (teal), 3. Melanin (purple), and 4. Melanoprotein (dark blue). Three white arrows point downwards from the right side of the first bar to the second, from the second to the third, and from the third to the fourth, indicating a sequential process.

DOPA

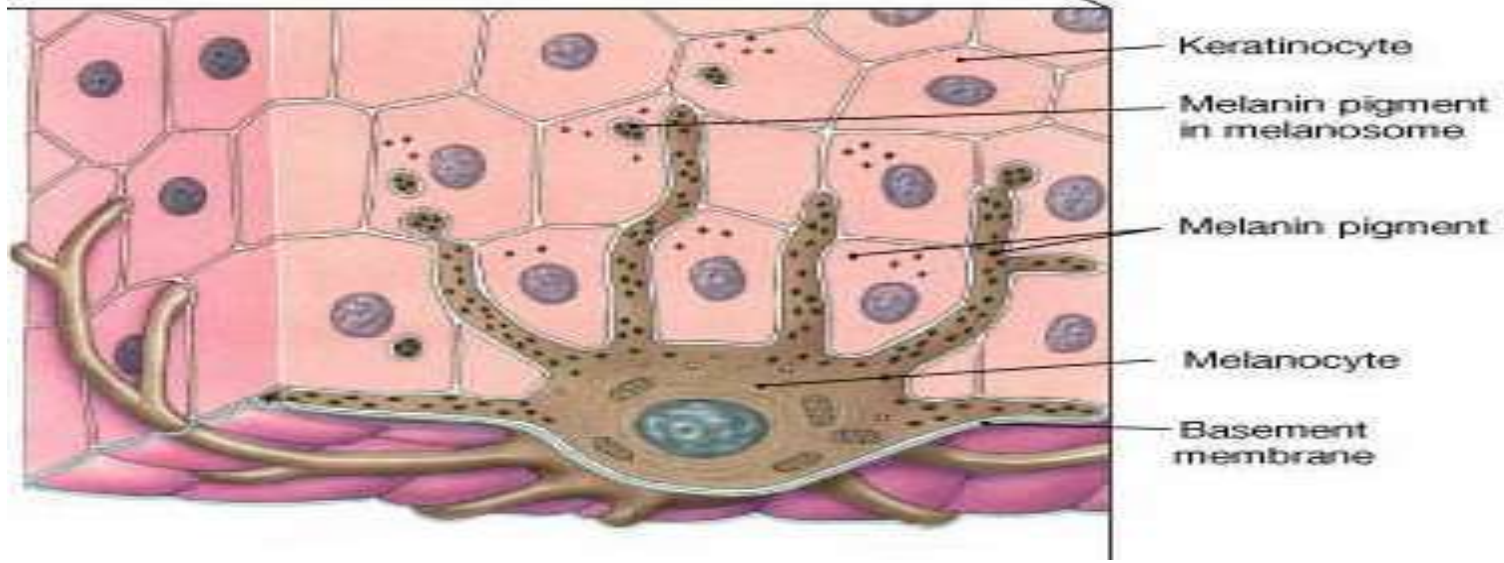
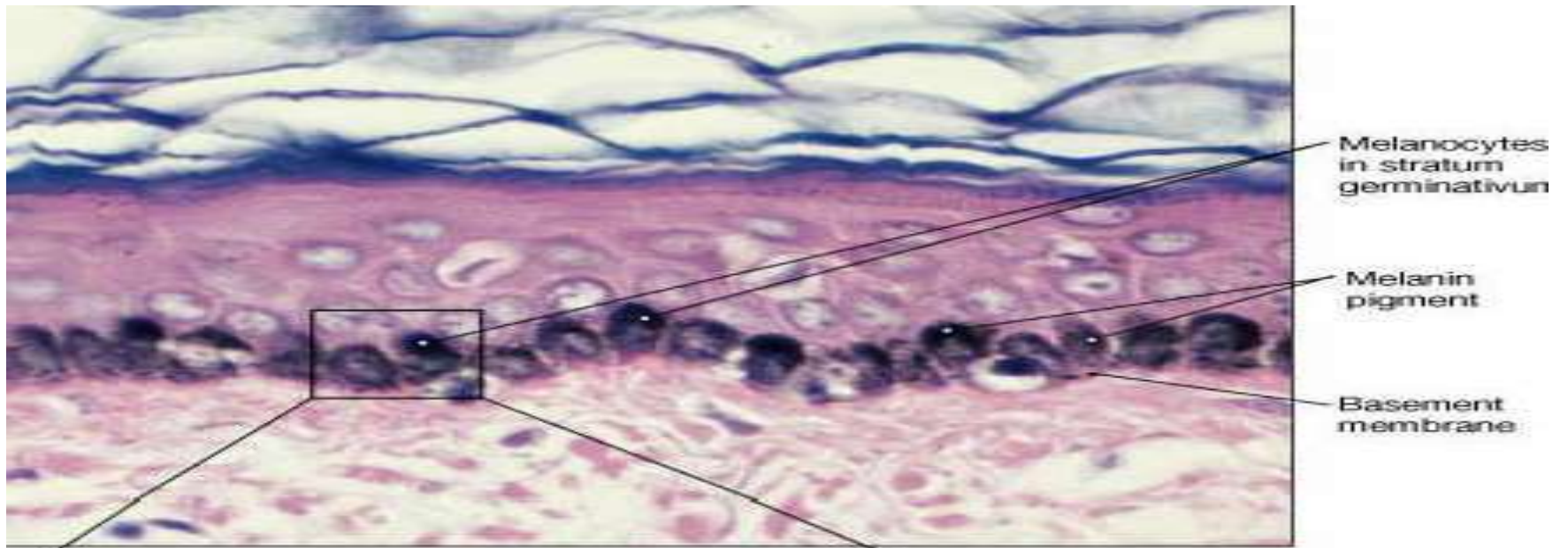
Melanin

Melanoprotein



EPIDERMAL MELANIN UNIT

- Ratio of Melanocytes to Keratinocytes in Epidermal basal layer **1:4 to 1:10** depending on the site of the body.
- Increases on repeated exposure to **UV light**
- **RACIAL DIFFERENCE**- due to differences in the amount of melanin contained in the Keratinocytes rather than the number of Melanocytes



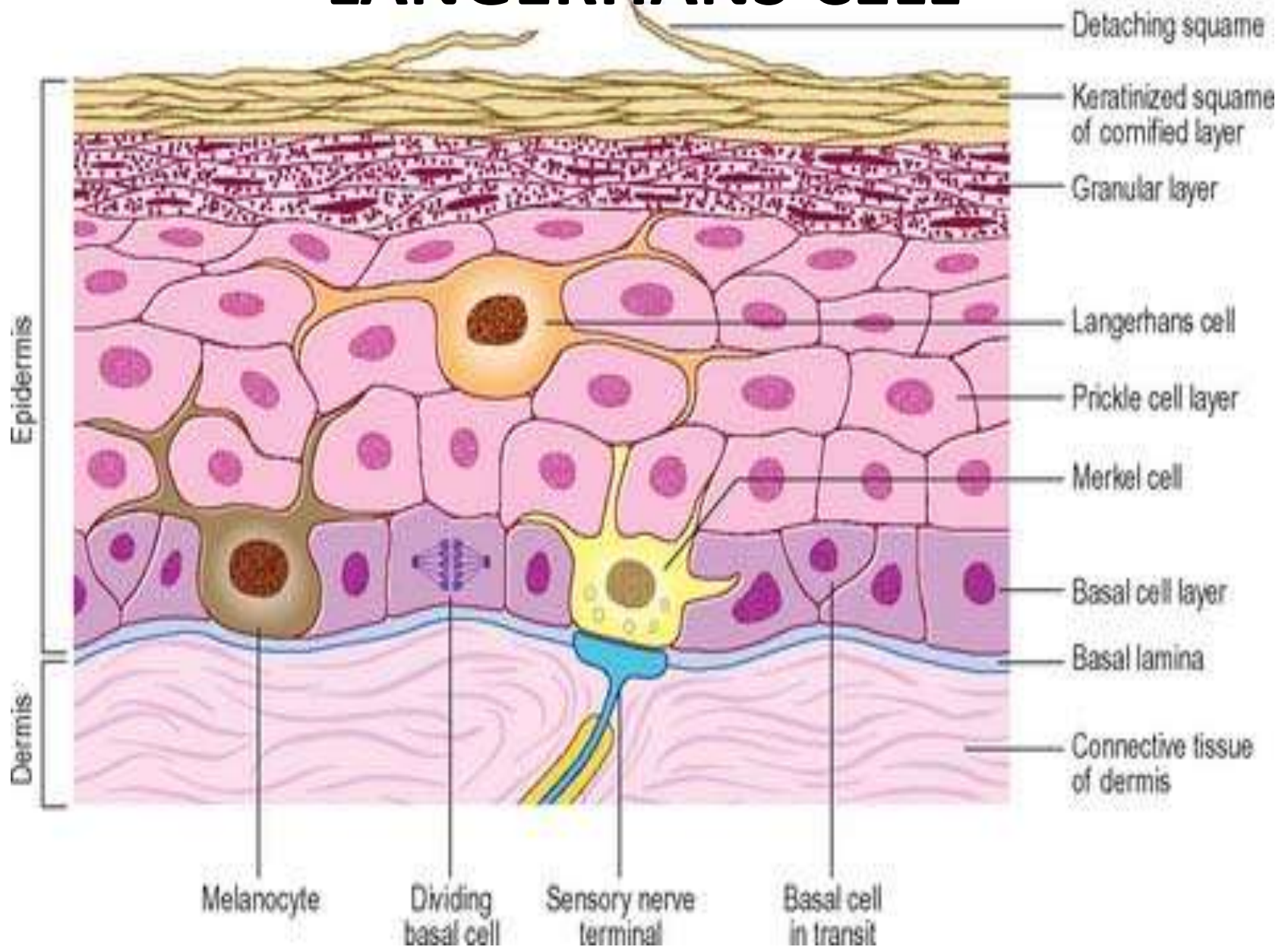
REGIONAL VARIATION

- The density of Melanocytes determined on **biopsy specimen 4mm** in diameter where epidermis is separated from the Dermis
- **HIGHEST CONCENTRATION** of Melanocytes
 - ✓ Face
 - ✓ Male genitals
- **LOWEST CONCENTRATION**
 - ✓ Trunk

LANGERHANS CELLS (Histiocytes)

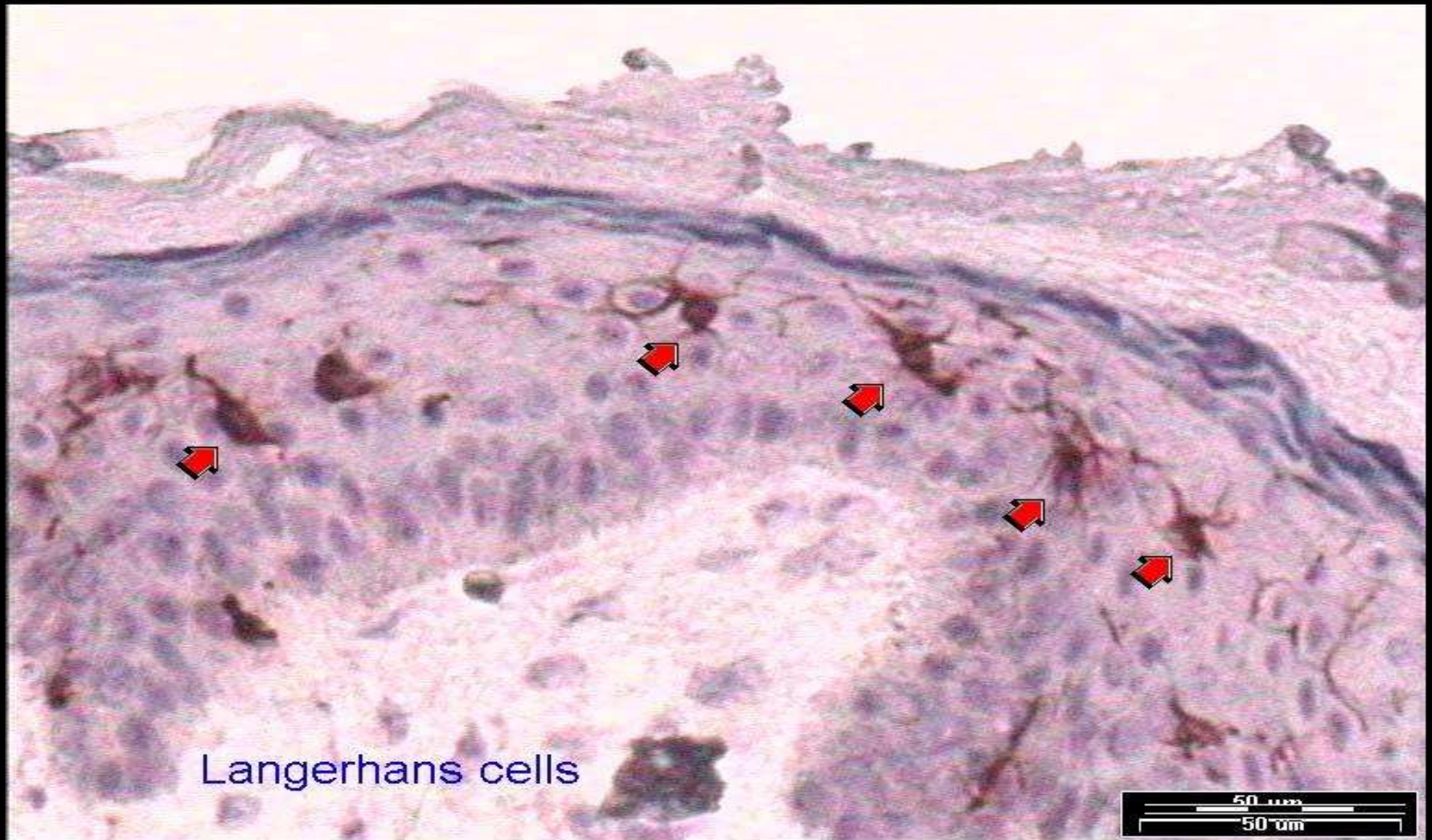
- Bone marrow derived Dendritic cells
- Intra- epidermal Antigen Presenting cells
- Difficult to see in routine H&E section
- All layers of the Epidermis, PRICKLE CELL LAYER

LANGERHANS CELL



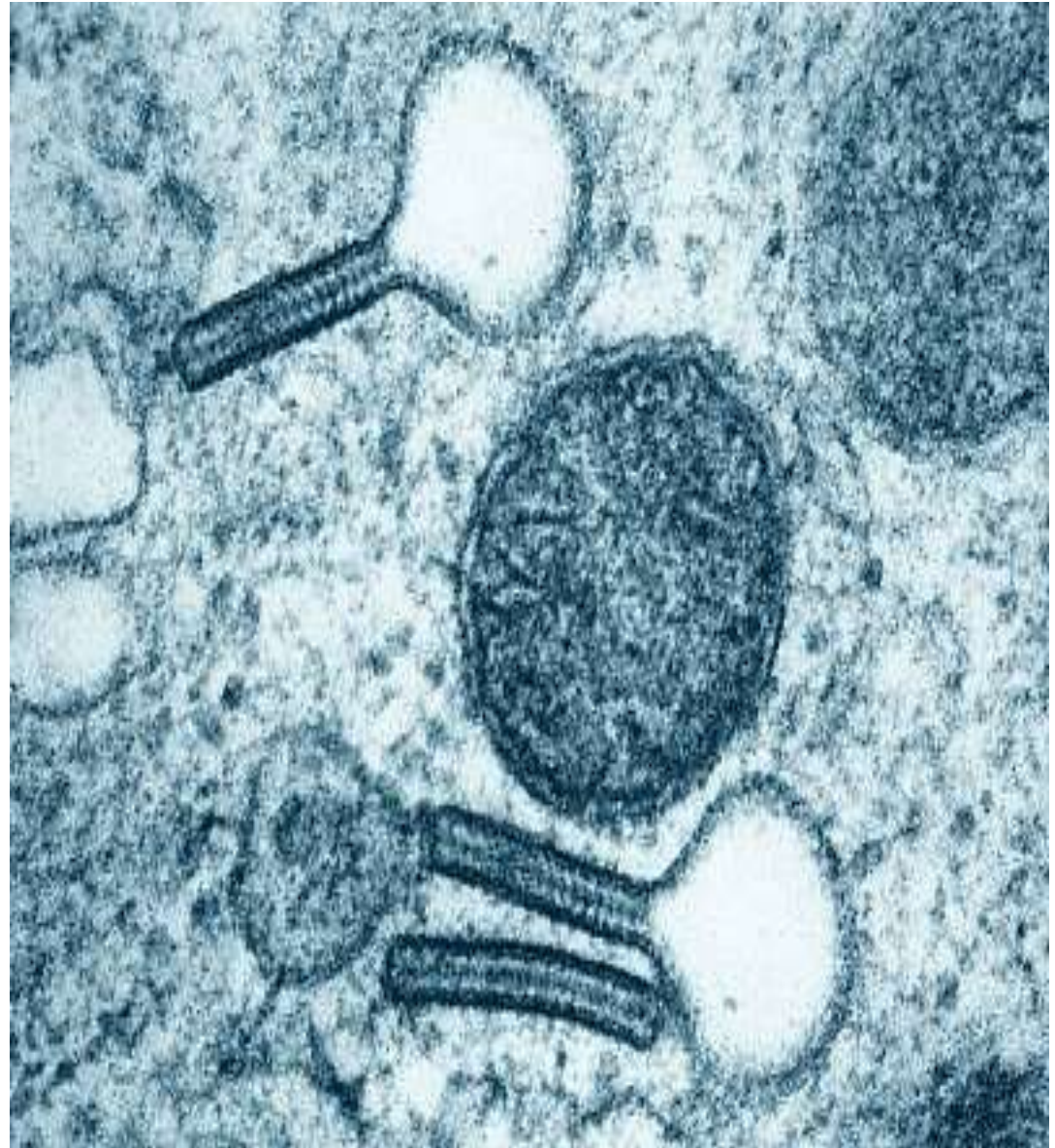
LANGERHANS CELL

- IHC- express CD1a, langherin & S-100 protein



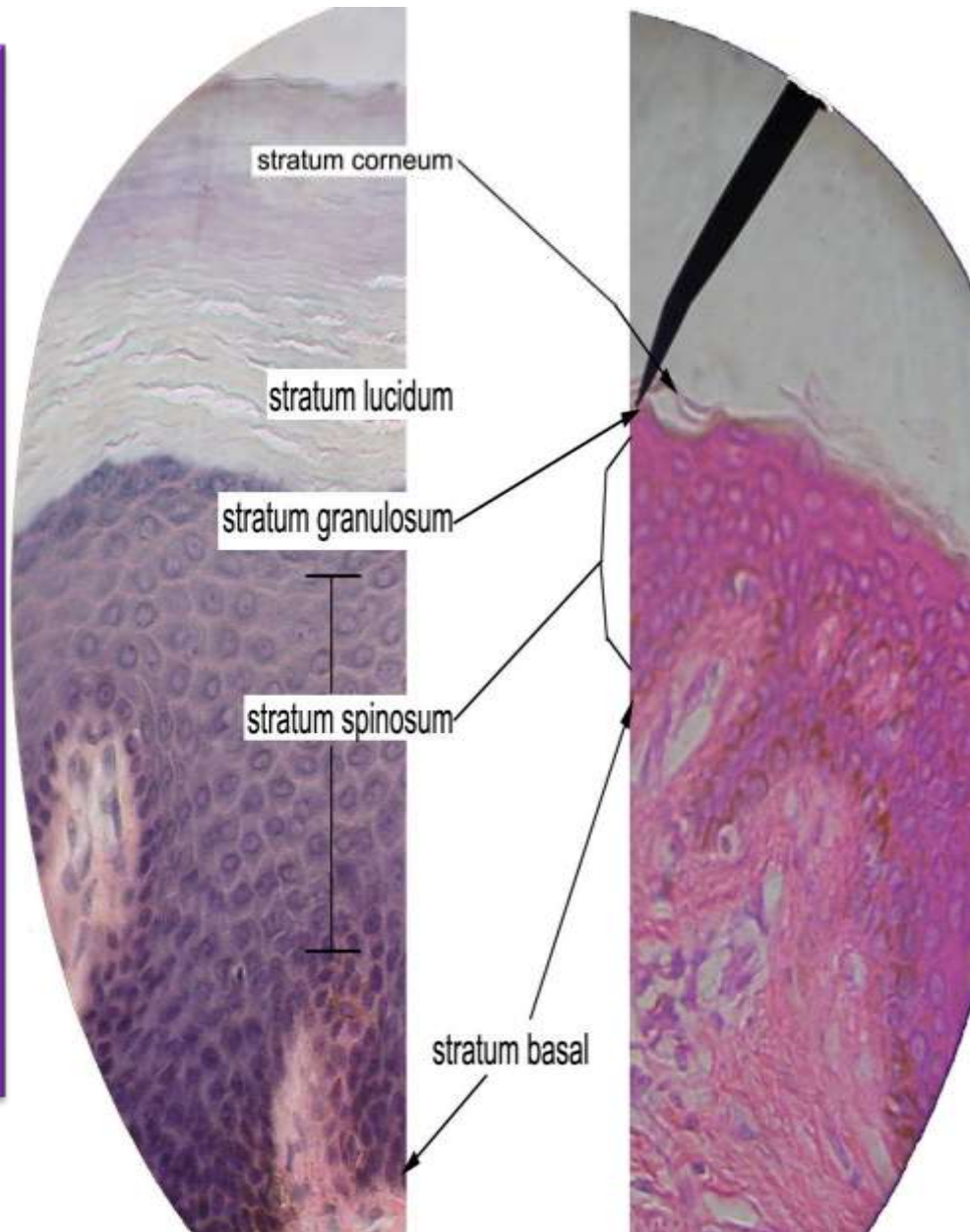
BIRBECK GRANULES

- EM- Characteristic Cytoplasmic organelle of Langerhans cells.
- Rod like –**zipper like** regular cross striations with bulbous end
 - **Tennis racket**



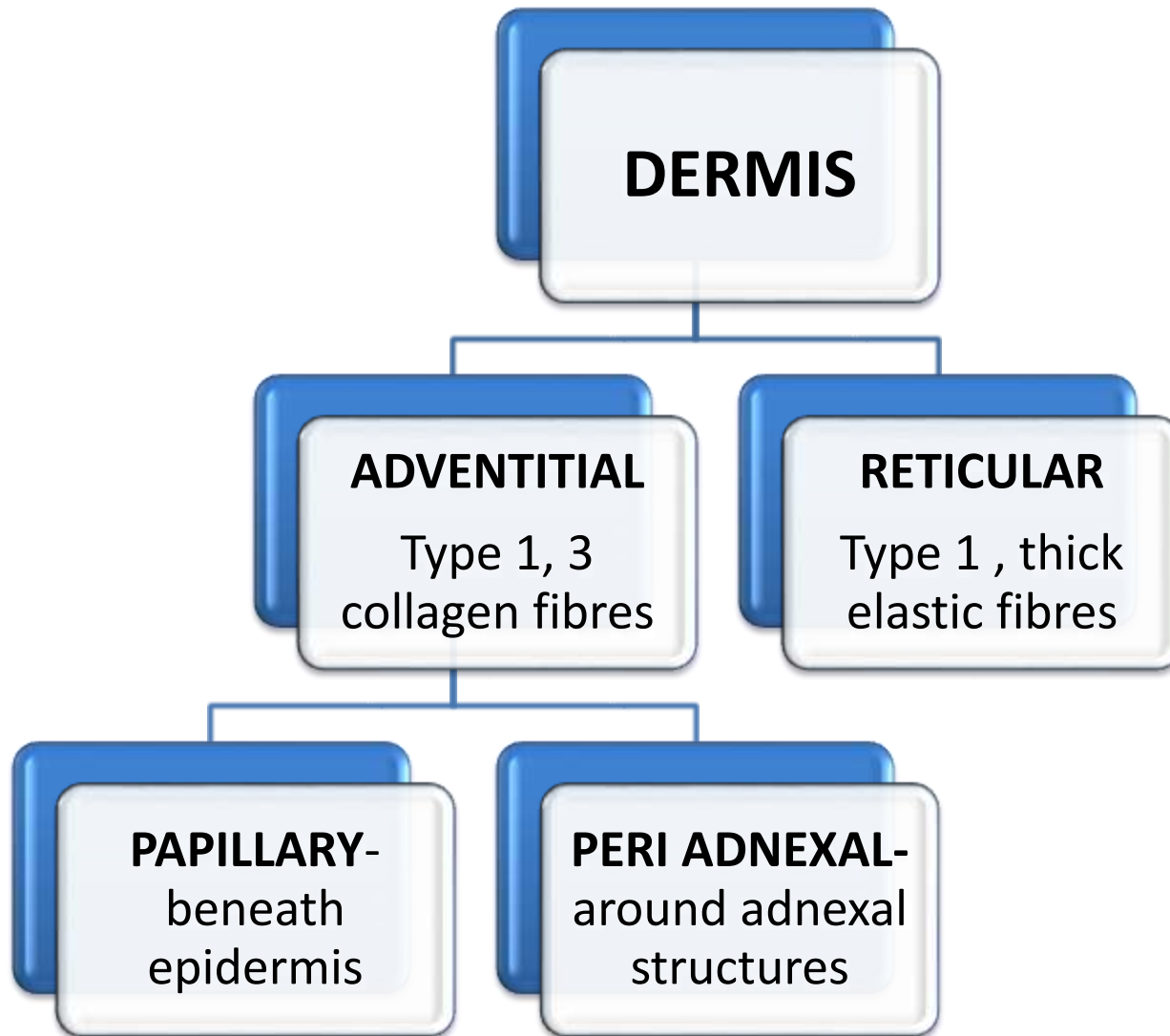
THICK SKIN

- * 5 layers
- * Prominent stratum corneum
- * Well developed stratum granulosum
- * Palms of the hands and soles of the feet
- * Thinner dermis
- * No hair and sebaceous glands



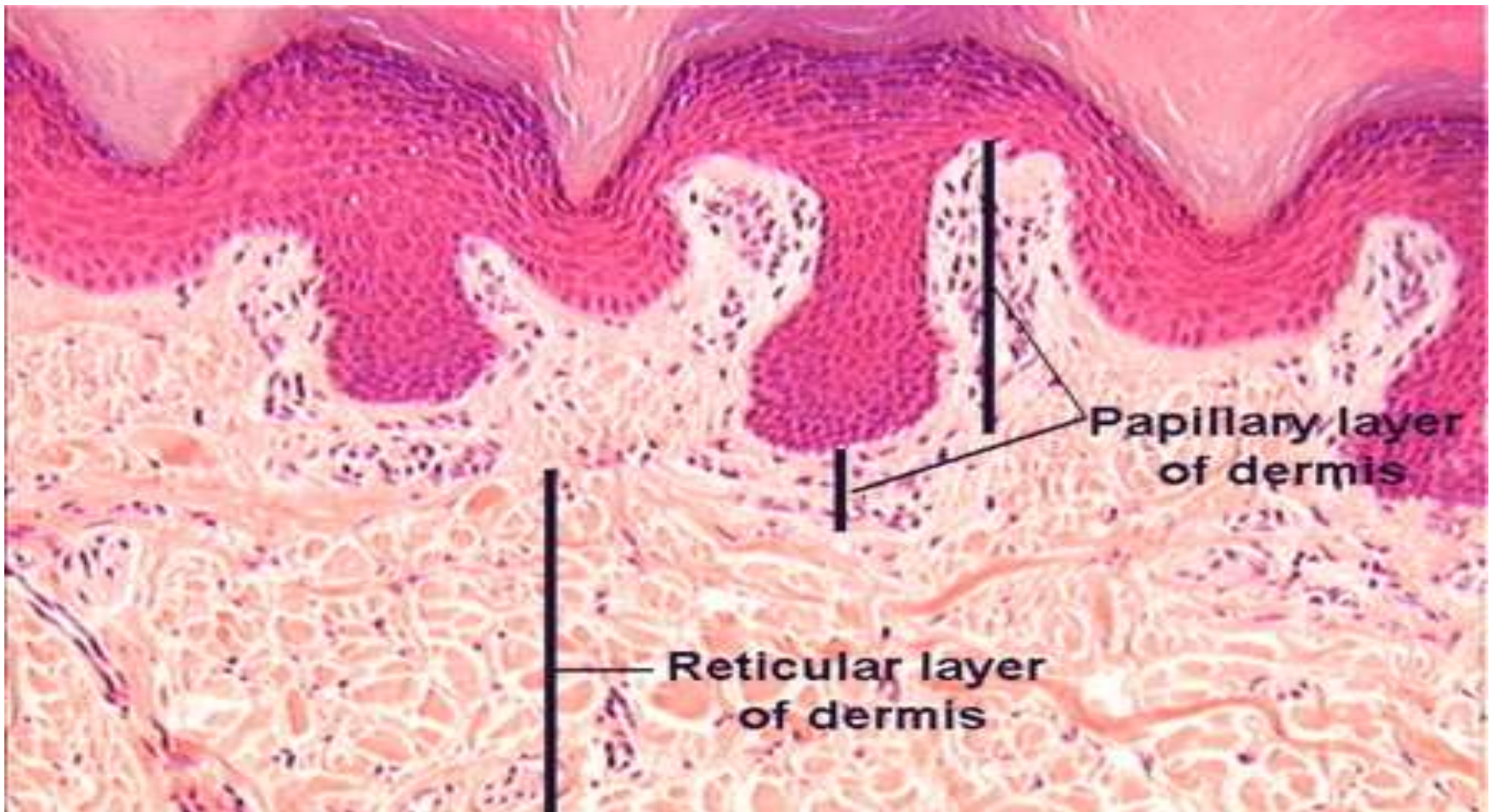
- * 4 layers
- * less Prominent stratum corneum
- * Less developed stratum granulosum
- * Dominant and lines most of the body surface
- * Thicker dermis
- * hair and sebaceous gland

THIN SKIN



DERMIS

- Bundles of **Collagen Fibres** & strands of **Elastic Fibres** embedded in scanty amount of acellular ground substance

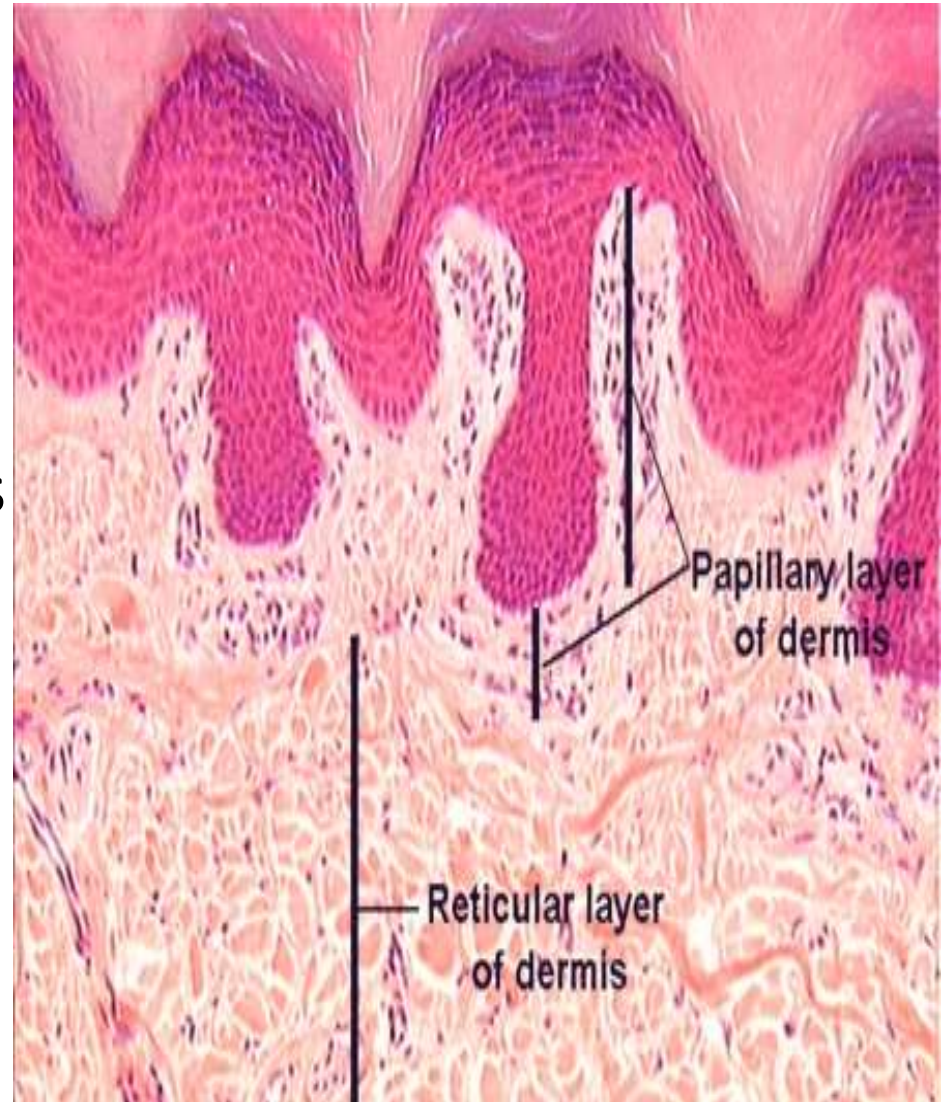


PAPILLARY DERMIS

- loose, very fine interlacing collagen (red) & elastic fibres (black) – EVG stain
- Support **avascular epidermis** with vital nutrients
- Provide network for **Thermoregulation**

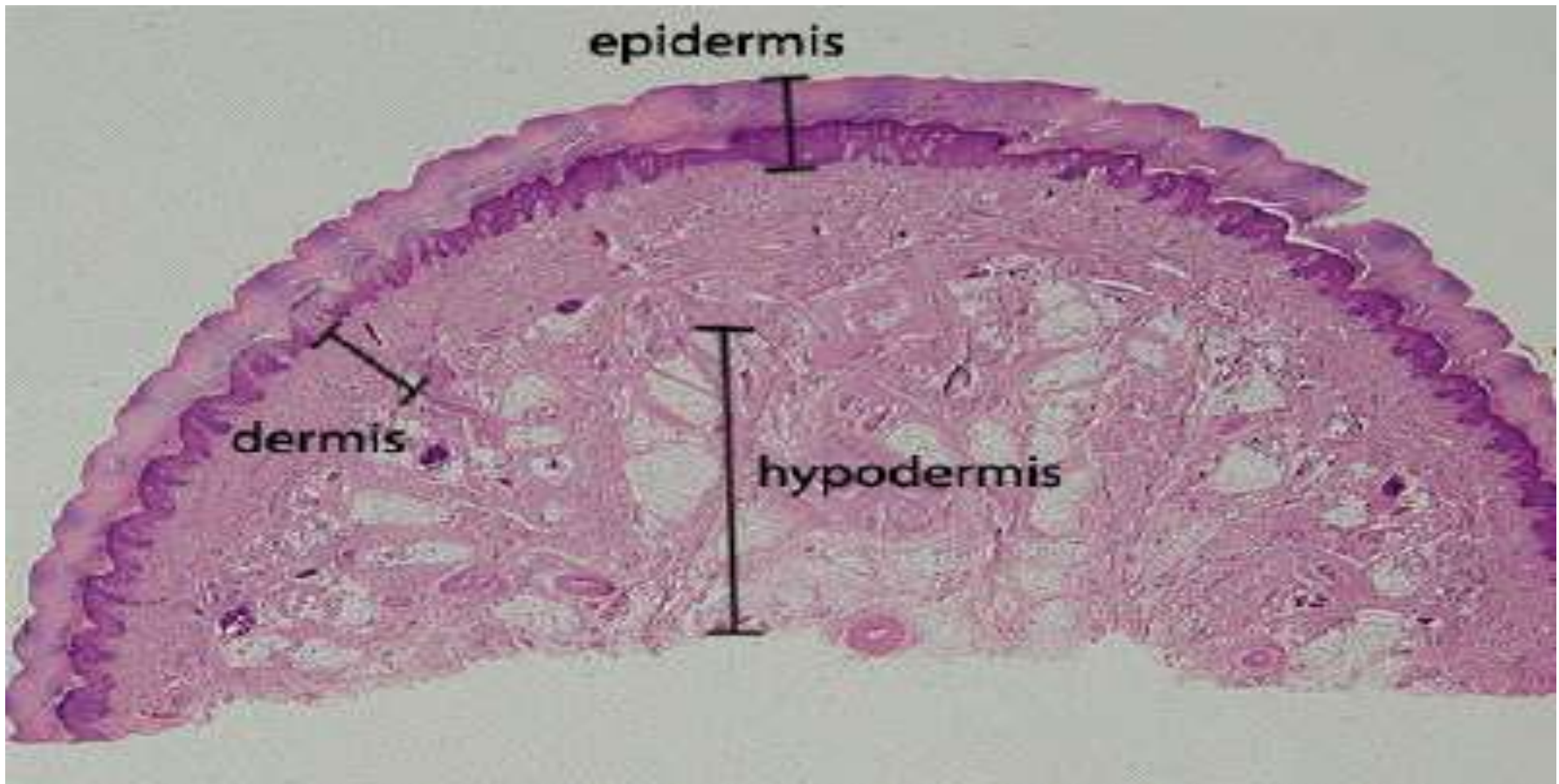
RETICULAR DERMIS

- **Larger** than Papillary Dermis
- blood vessels, nerves & Skin **appendages**
- Lymphocytes, mast cells & macrophages- scarce in N, increased in skin disease
- Thickest on the Back & thinnest in the Eyelids



SUBCUTIS (HYPODERMIS)

- Lobules of **mature Adipose tissue** separated by thin bands of connective tissue-like **interlobular septa**
- Varies from site to site
- No hair follicles or apocrine glands



DERMAL BLOOD VESSELS

Superficial plexus

- Papillary dermis
- Capillary loops extend into Dermal papilla

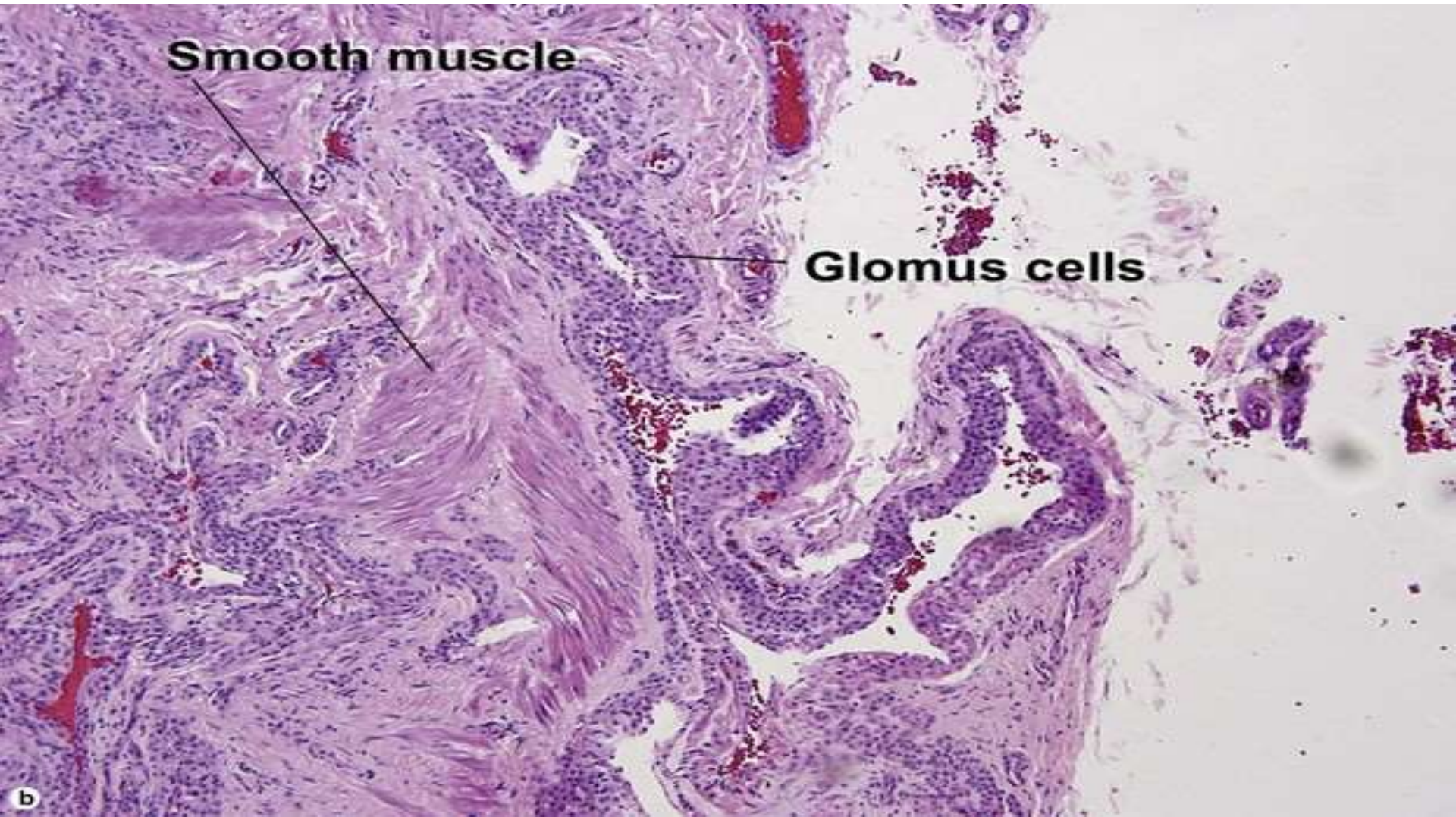
Deep plexus

- Reticular dermis

- Acral Skin contains specialised arteriovenous anastomosis- **SUCQUET HOYER CANAL**
- They are surrounded by a row of modified smooth muscle- the **GLOMUS CELLS**- round, clear cytoplasm & well defined cytoplasmic borders

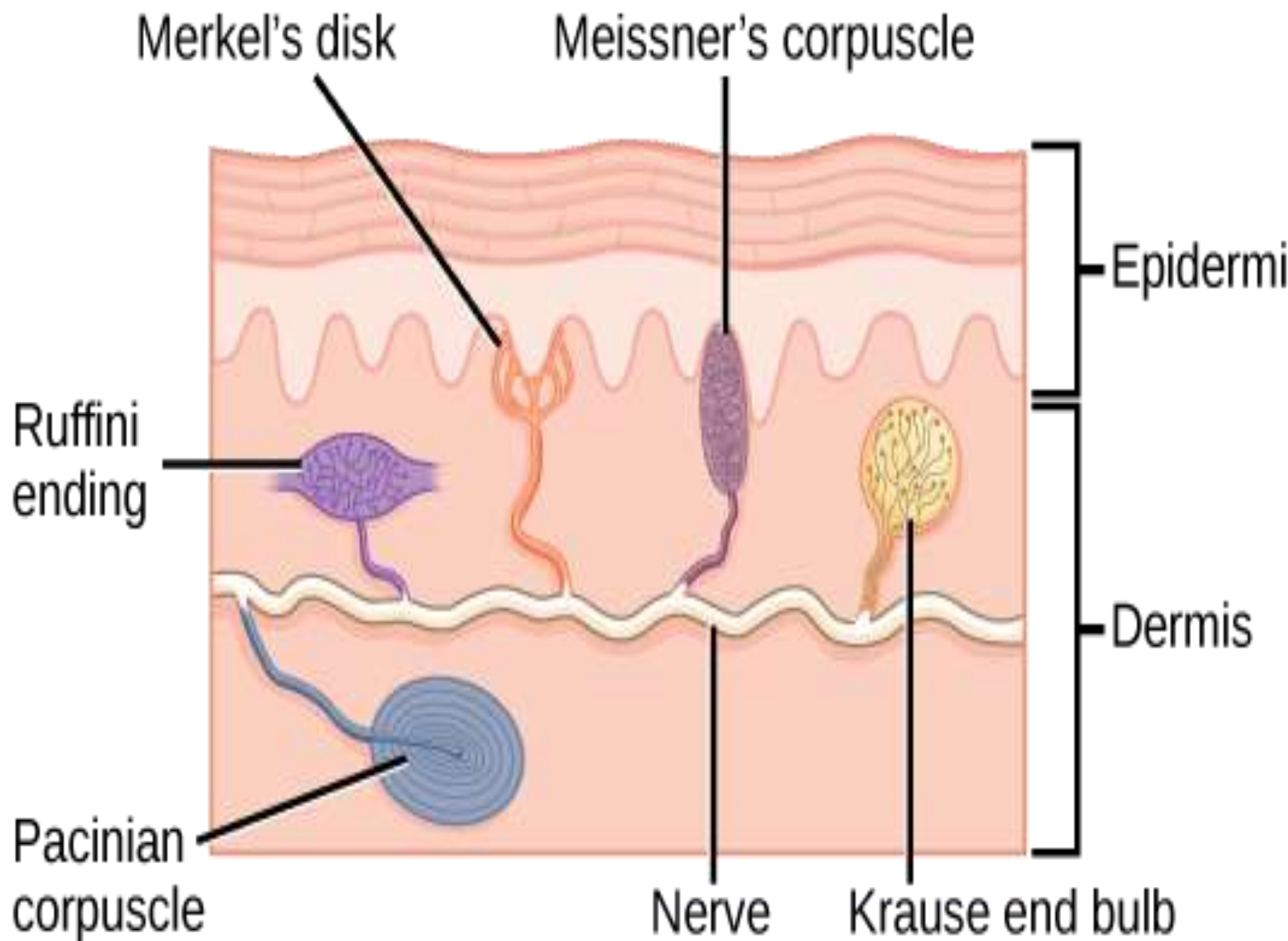
GLOMUS CELLS

- **GLOMUS CELLS**- round, clear cytoplasm & well defined cytoplasmic borders



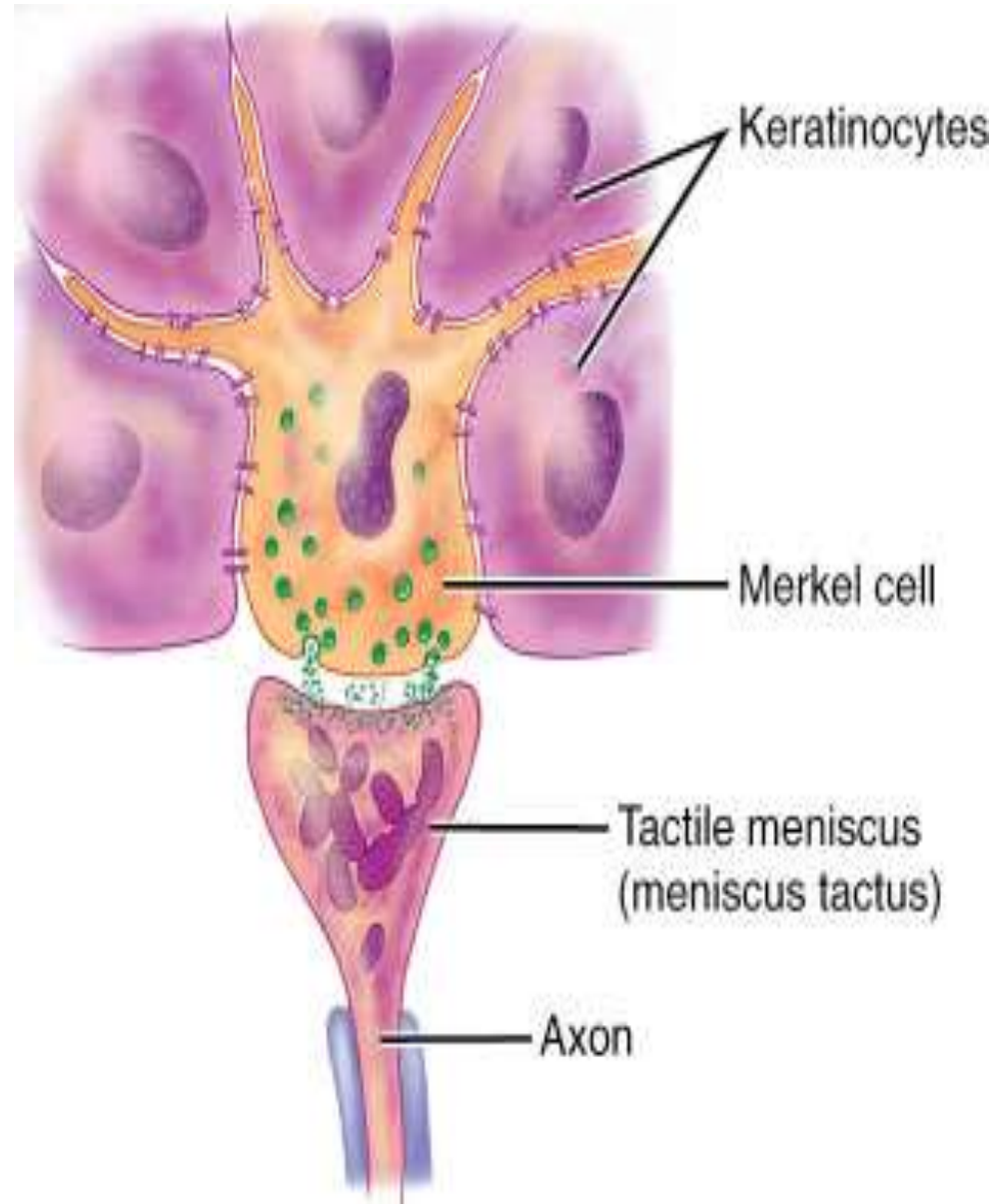
INNERVATION & NERVE ENDINGS

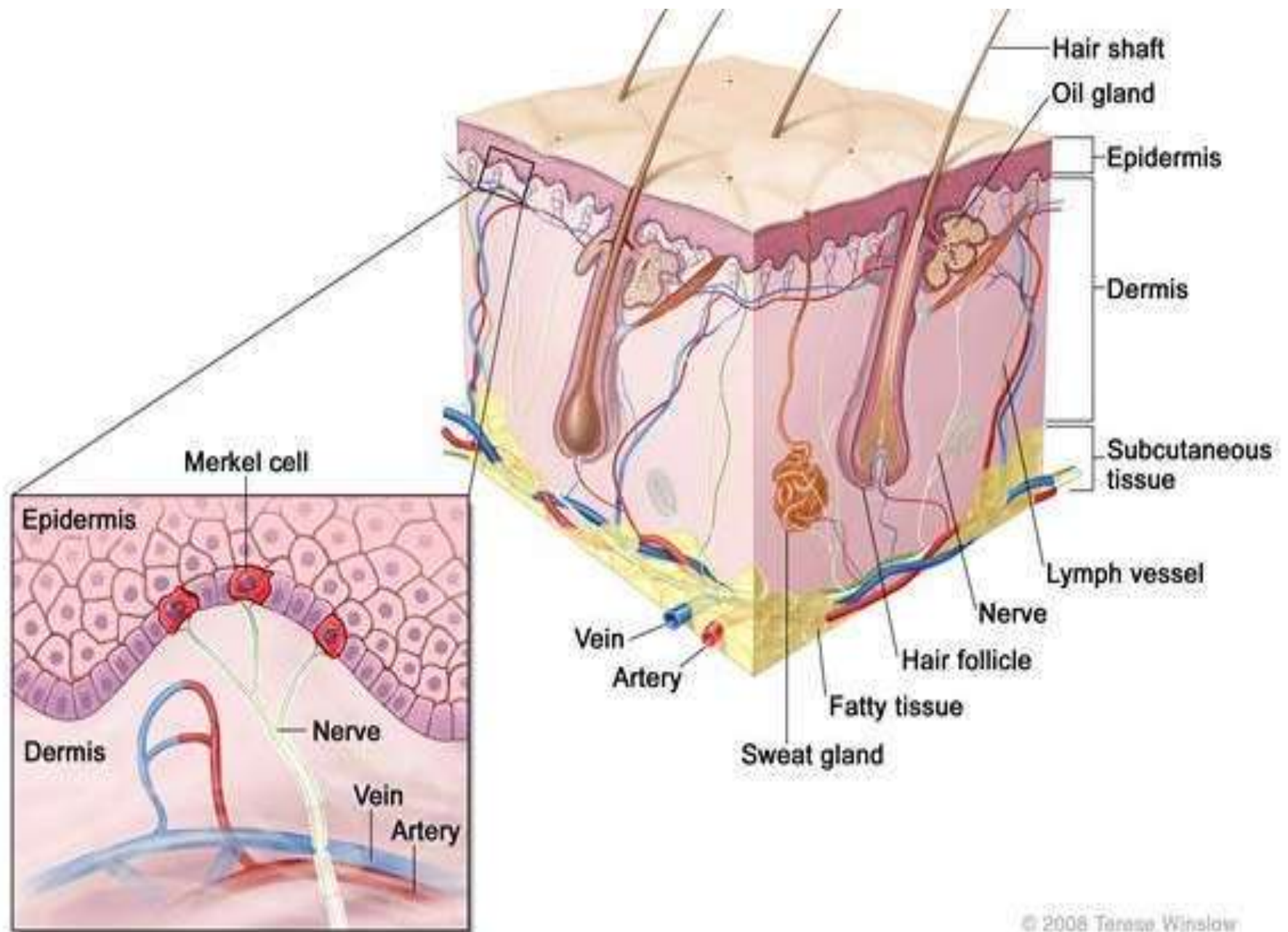
- SENSORY NERVE ENDINGS IN SKIN:
 - ✓ Free nerve endings
 - ✓ Specialised encapsulated nerve endings
 - 'Capsule'- modifications of Schwann cells
 - Meissners Corpuscles
 - Pacinian Corpuscles
 - Ruffini nerve endings



MERKEL CELLS

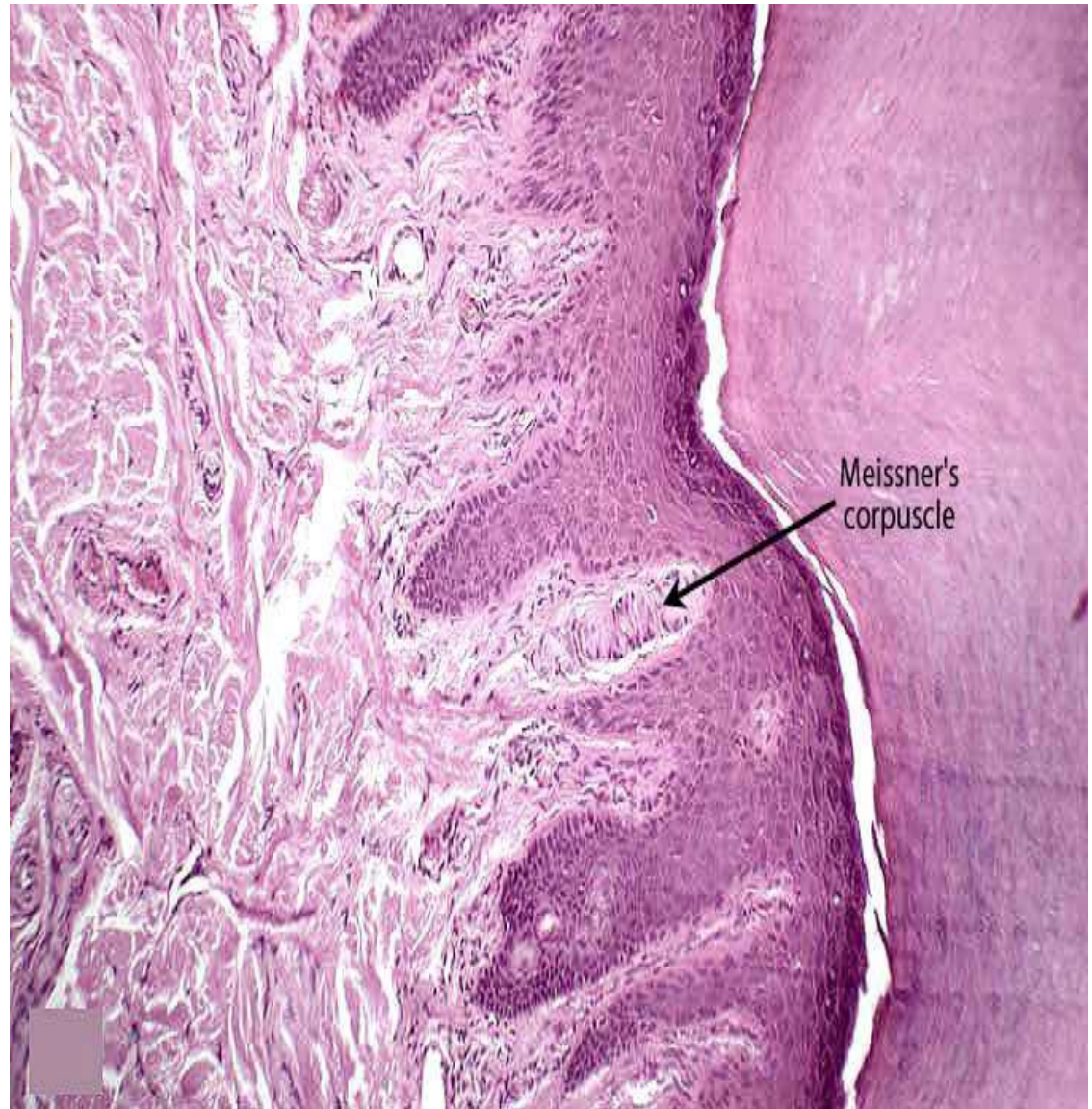
- Intra- epidermal **touch receptors**
- Contain Neuro endocrine type **membrane bound vesicles (dense core granules)** in their cytoplasm
- Difficult to detect in H&E sections

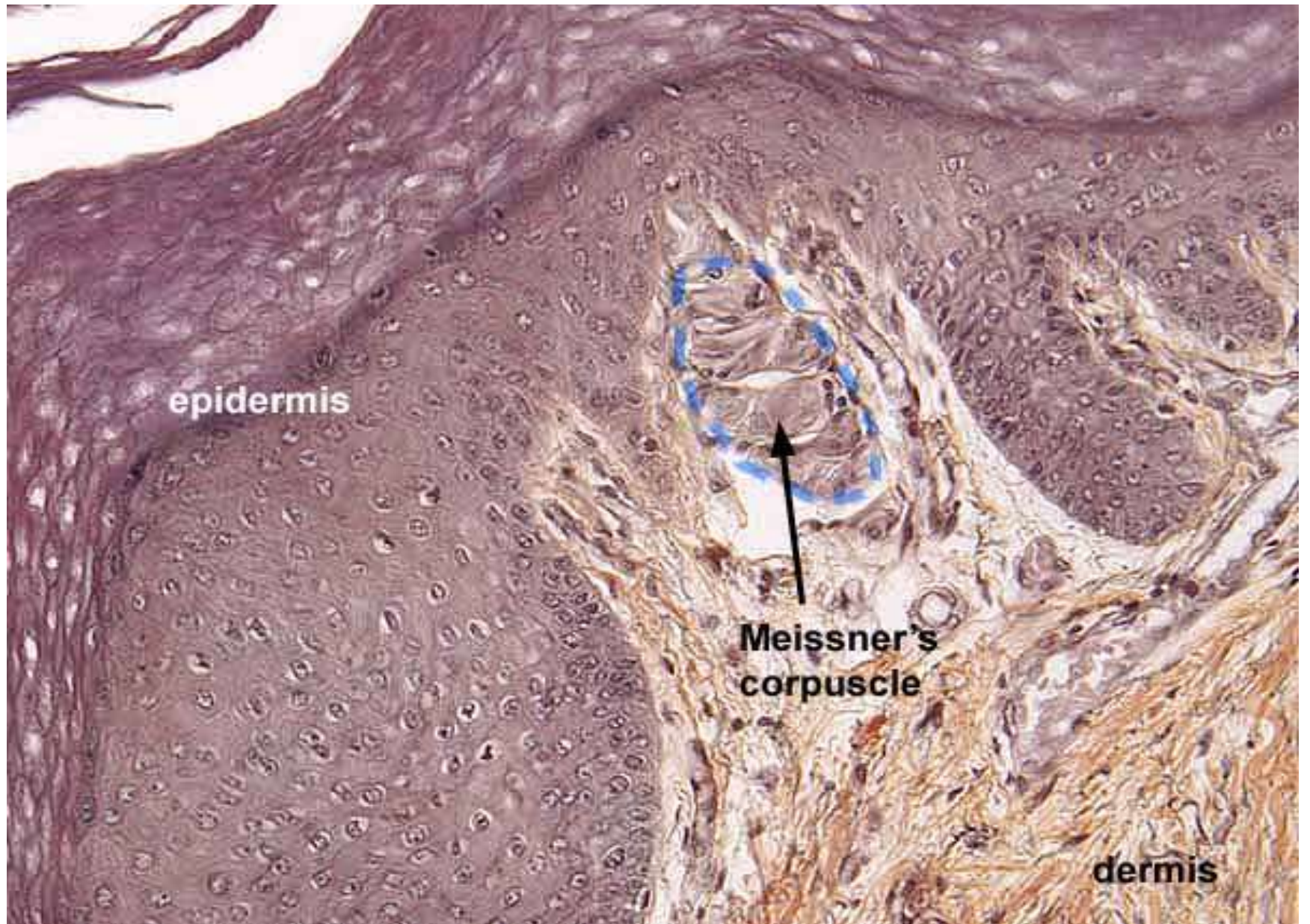




MEISSNERS CORPUSCLES

- Rapidly adapting Mechanoreceptor
- **Touch sensation**
- Papillary Dermis – Pulp of the fingers and toes & soles and Palms





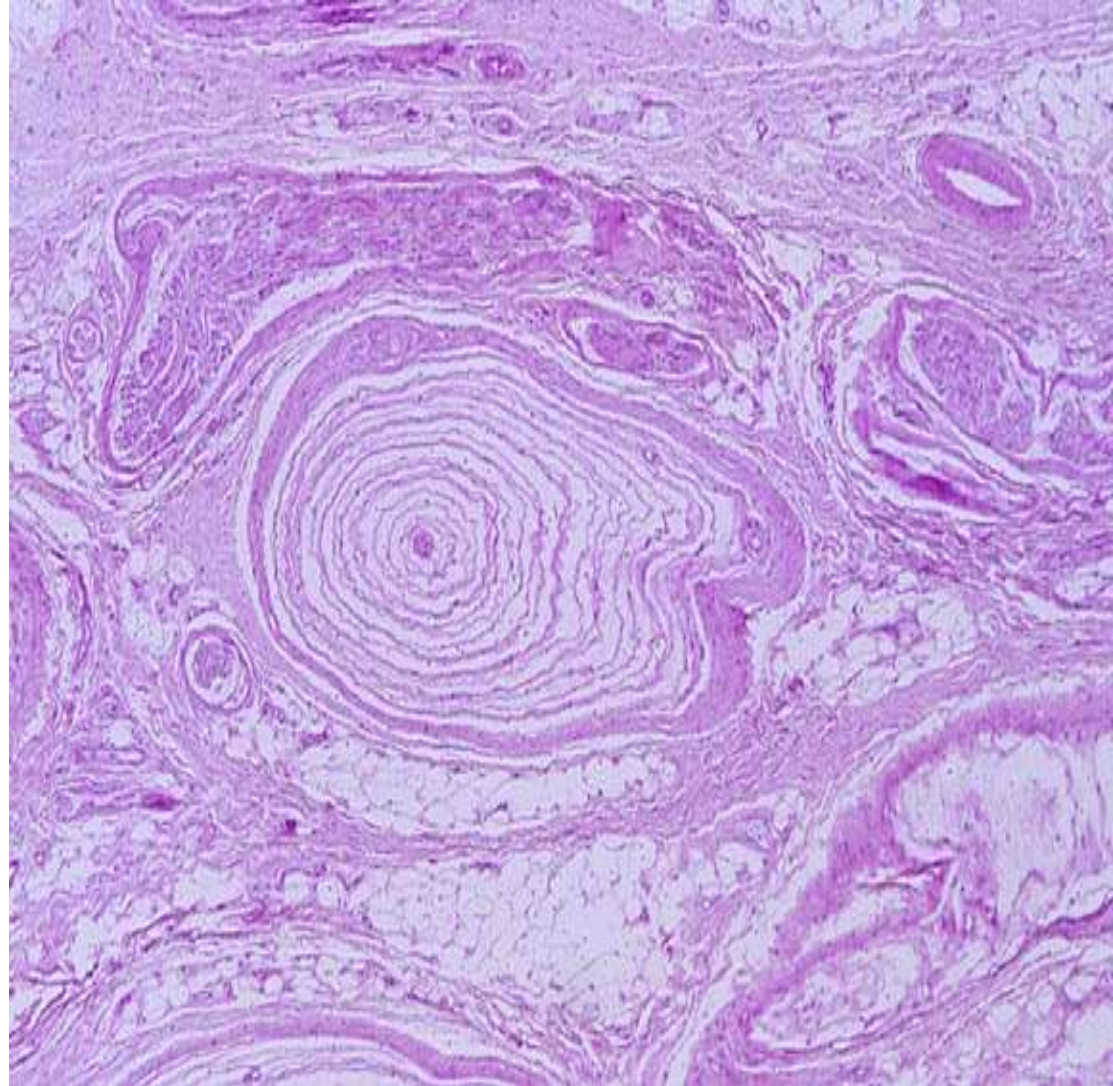
epidermis

Meissner's
corpuscle

dermis

PACINIAN CORPUSCLES

- Deep pressure & Vibration
- Deep in the subcutis- singly or in clusters
- Numerous in Palms & soles



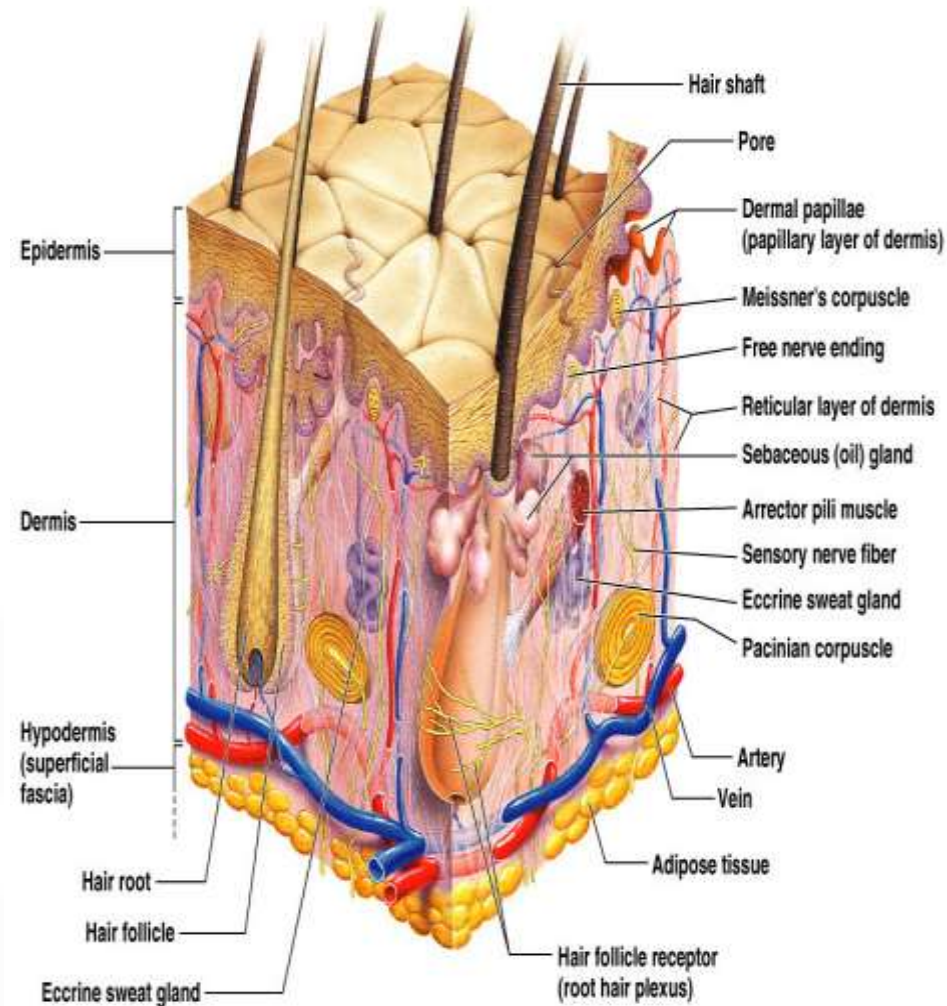
SKIN APPENDAGES (ADNEXA)

Hair Follicles

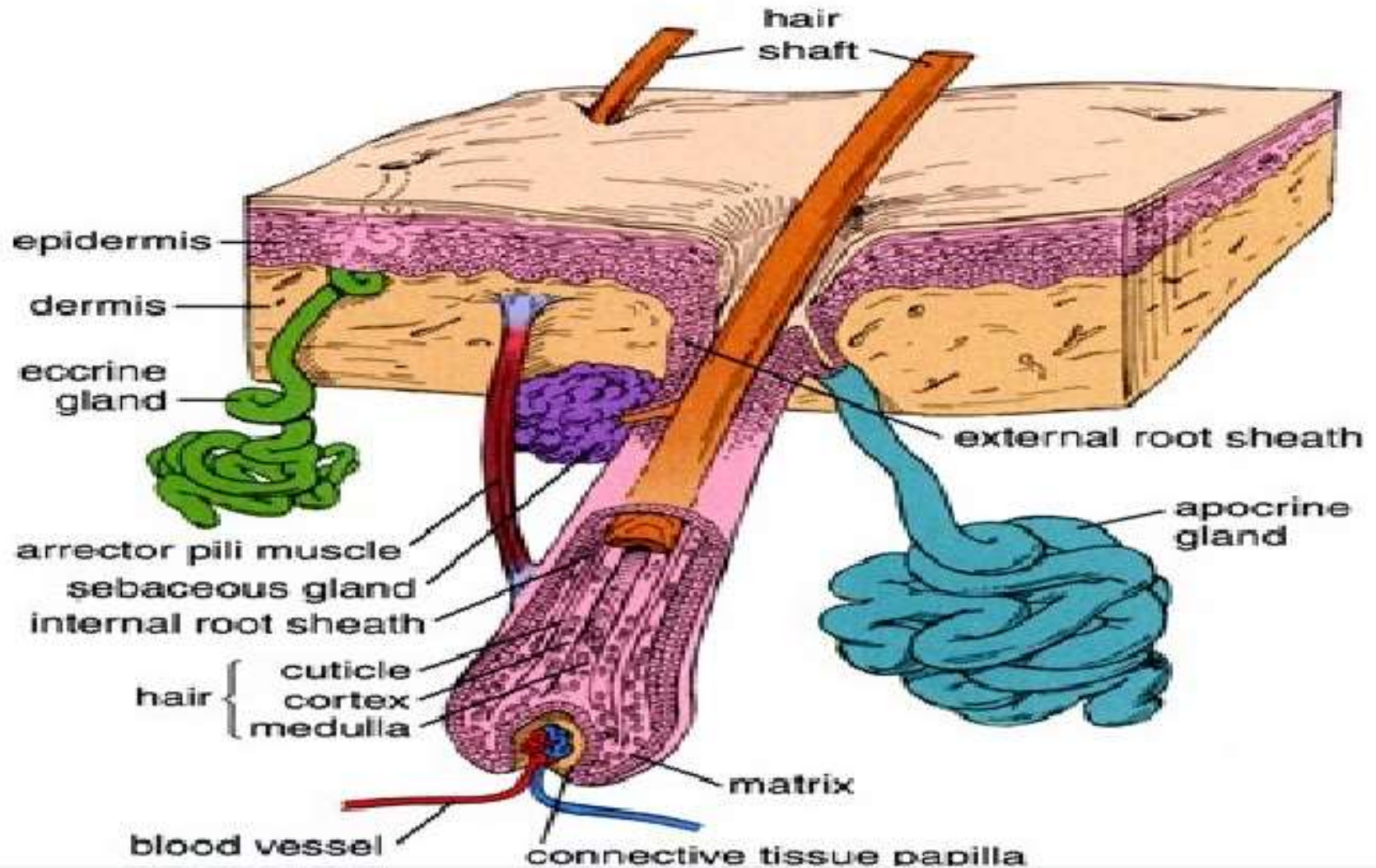
Sebaceous glands

Eccrine glands
(Sweat glands)

Apocrine glands



SKIN APPENDAGES (ADNEXA)



PILAR UNIT

- Functional complex

Hair follicle

Sebaceous gland

Arrector pili muscle

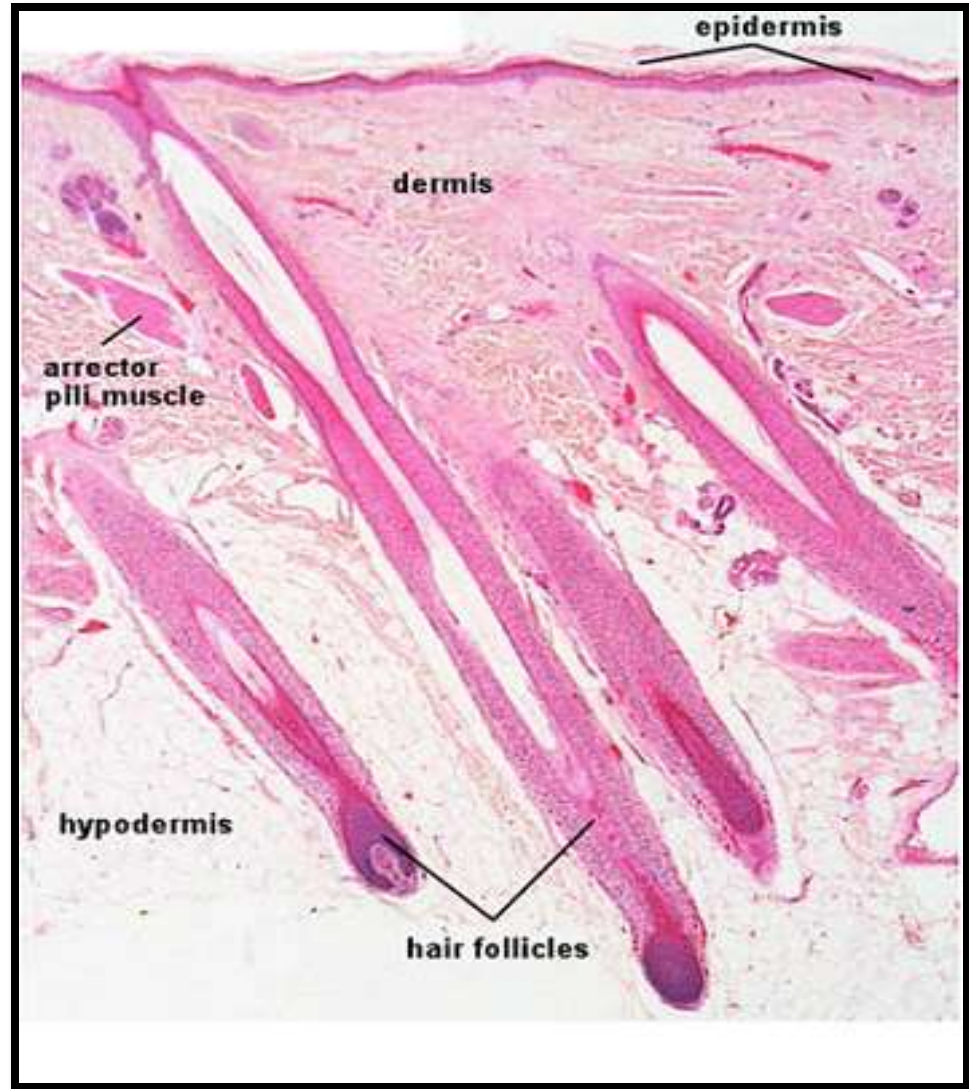
Apocrine glands (certain region)

HAIR FOLLICLE

- Tubular formed structure formed of Perifollicular connective tissue & epithelium
- Hair papilla
- Hair Matrix
- **Inner three** epithelial undergo **Keratinisation**
→ Hair Shaft
- **Outer two** layers → Internal & External root sheath

HAIR FOLLICLE

- Long thin cylindrical structures (Hair Shafts)
- Keratin arranged in an organised manner
- HAIR SHAFT
 1. Central MEDULLA
 2. CORTEX
 3. Surface CUTICLE-
single layer of flattened scales



PARTS OF HAIR FOLLICLE

(in longitudinal section)

LOWER PORTION

- Base of Hair follicle
- Insertion of Arrector pili muscle

ISTHUMUS

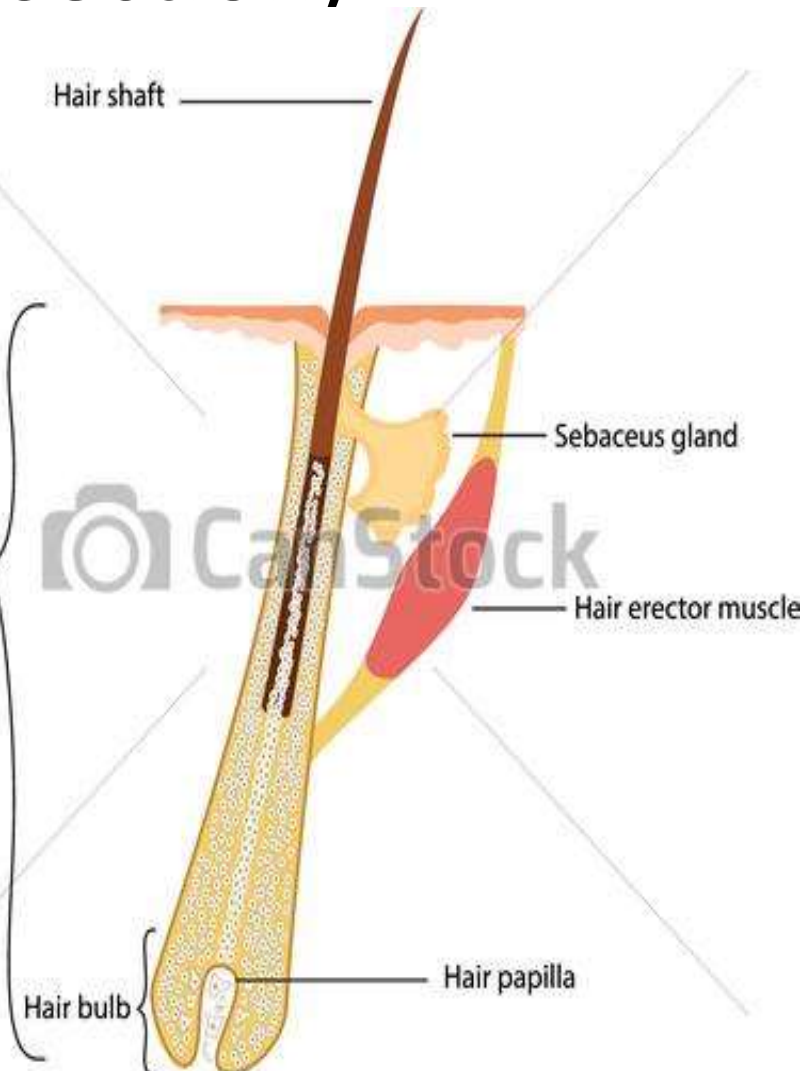(middle portion)

- Arrector pili
- Entrance of Sebaceous duct

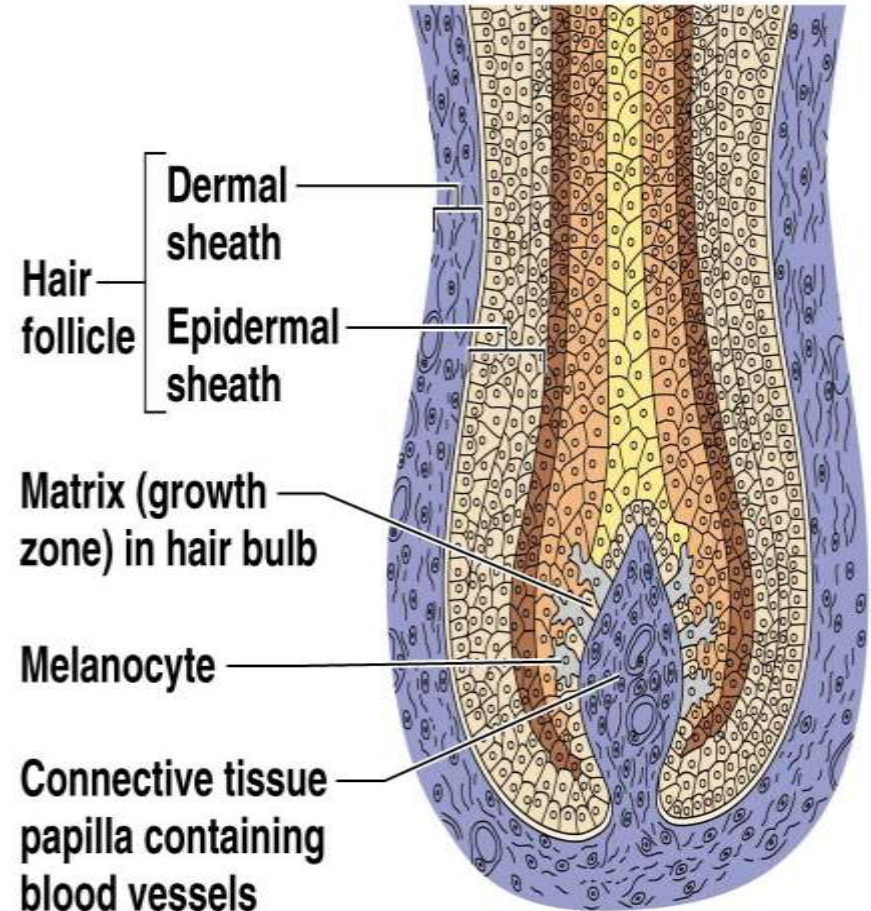
INFUNDIBULUM

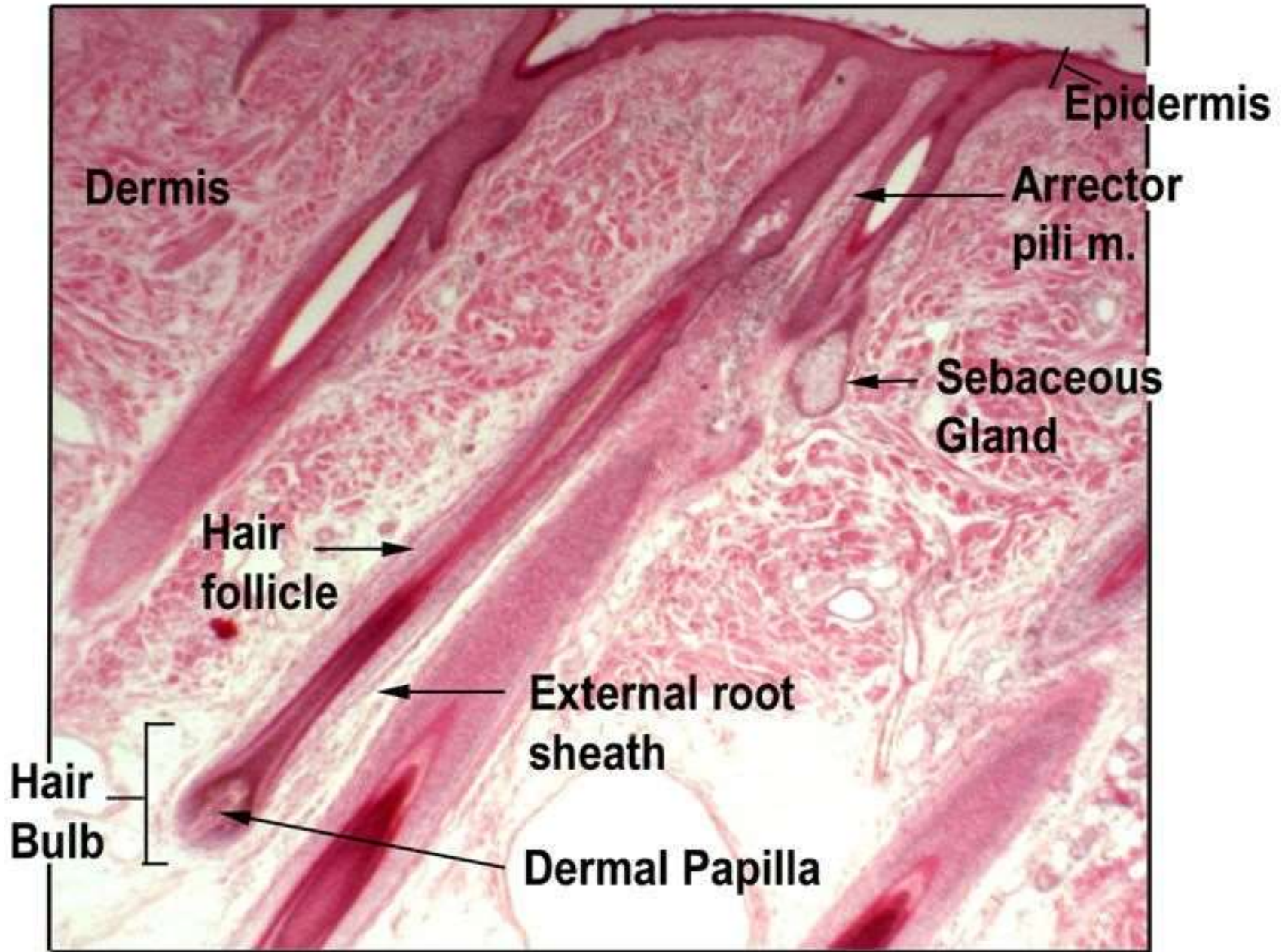
(upper portion)

- Entrance of Sebaceous duct
- Follicular orifice



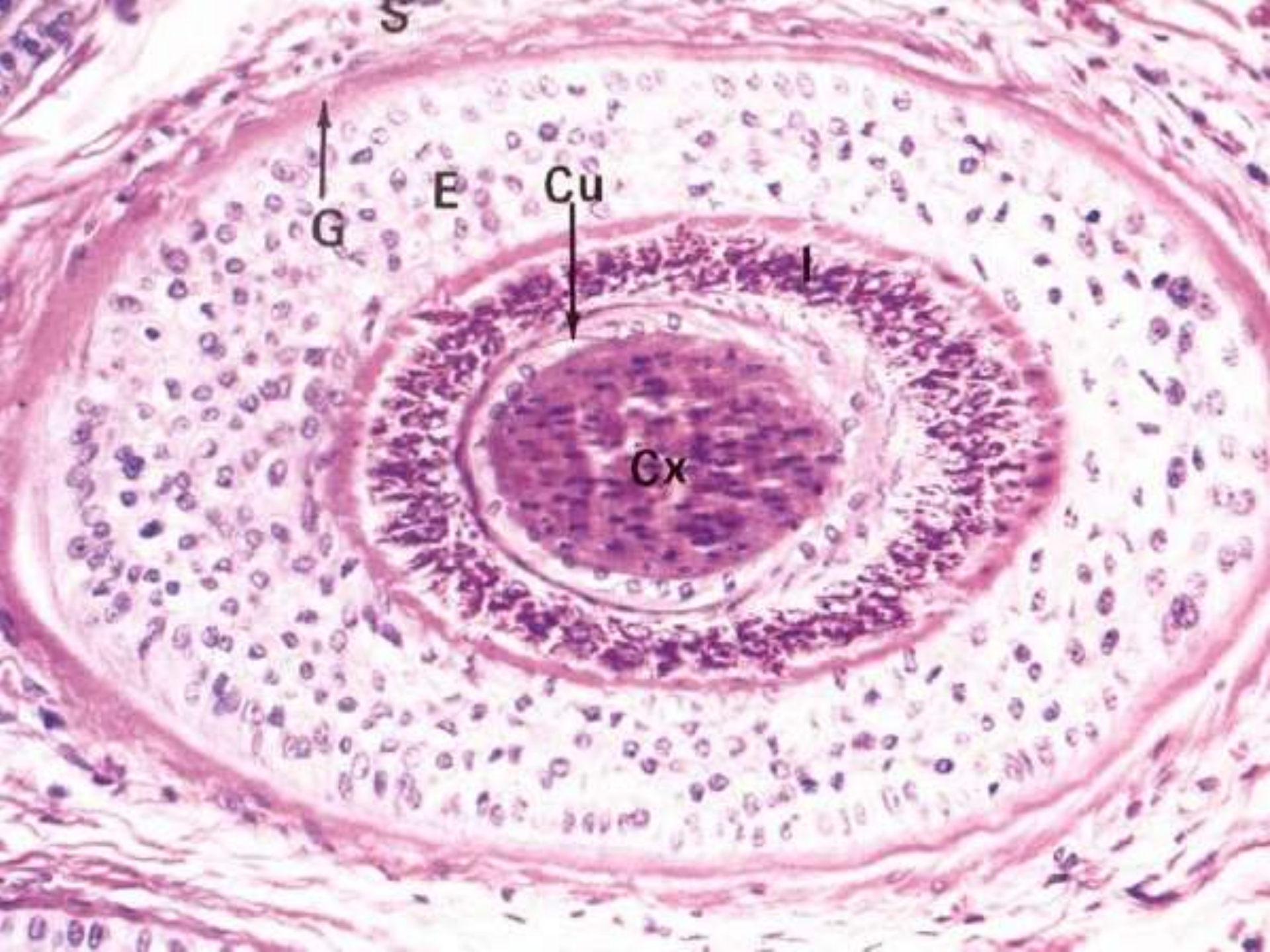
- **HAIR BULB**- At the base, there is Bulbous expansion. Encloses **HAIR PAPILLA**
- **HAIR MATRIX**- at hair bulb, all the layers merge
- **HAIR ROOT**- epithelial mass surrounding the Dermal papilla

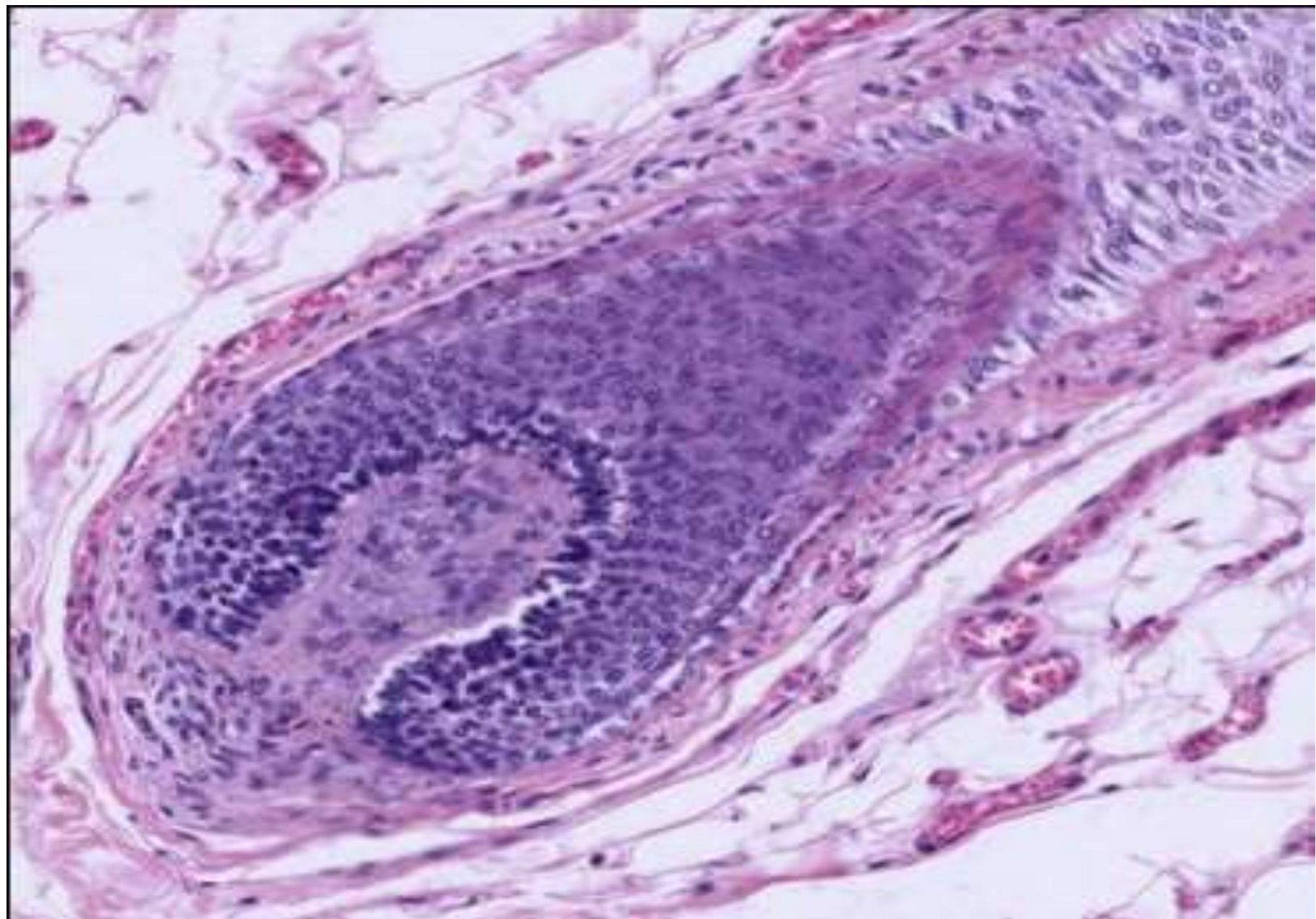


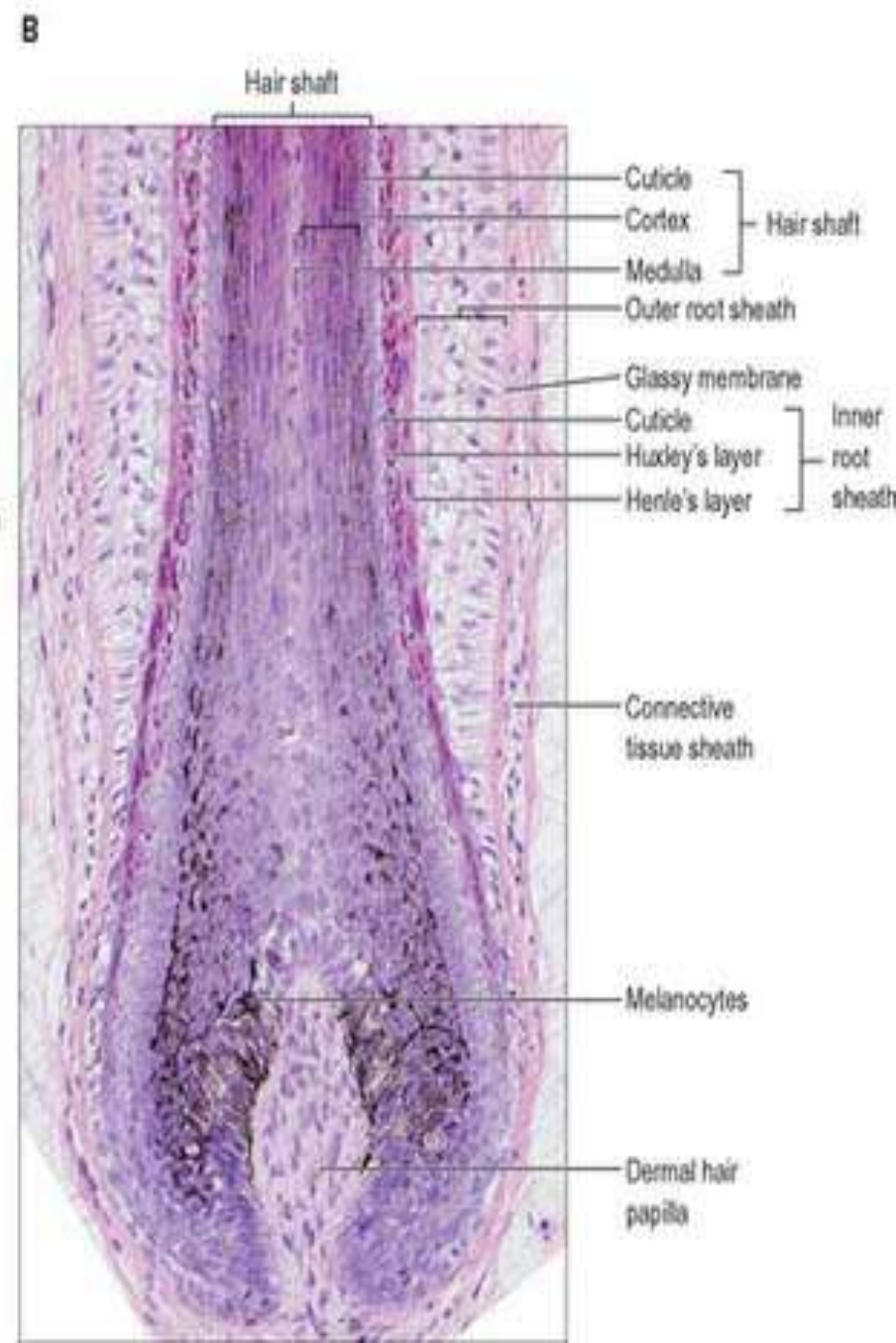
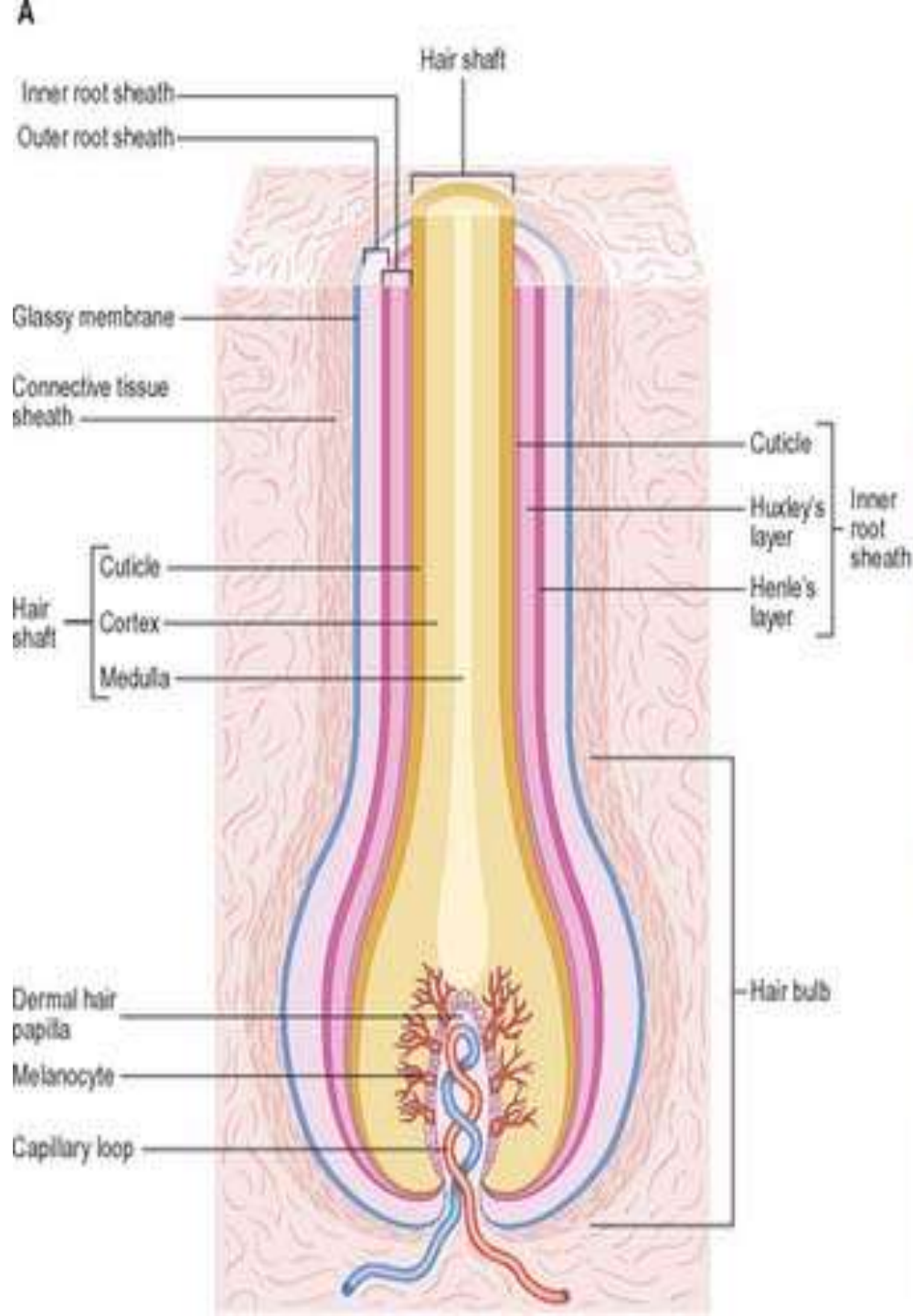


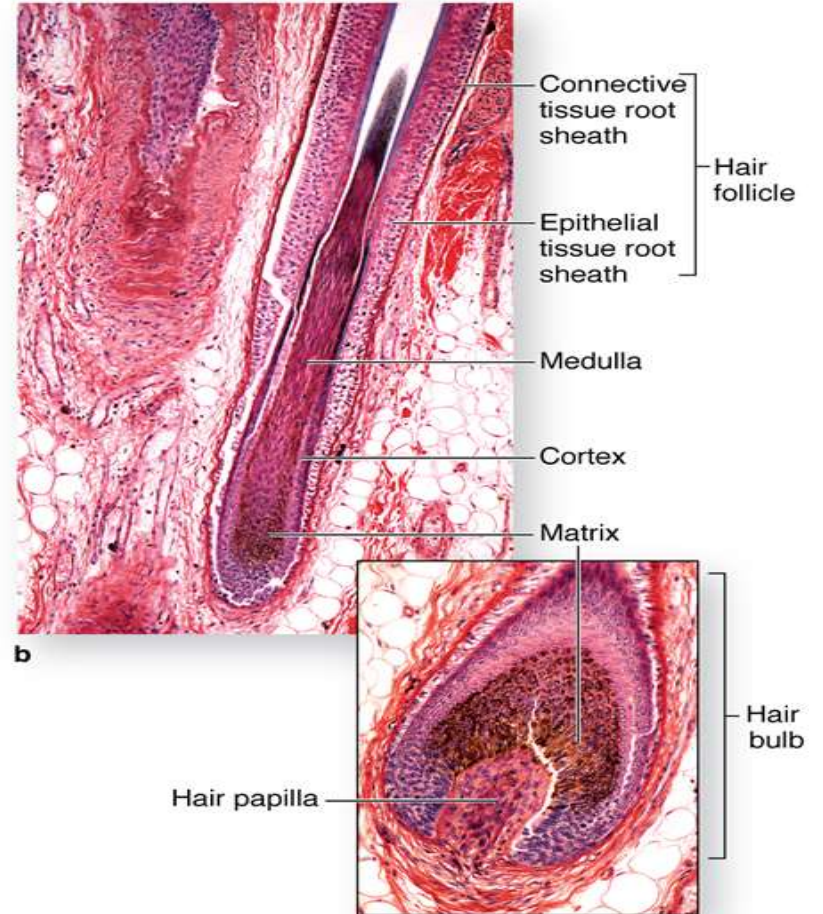
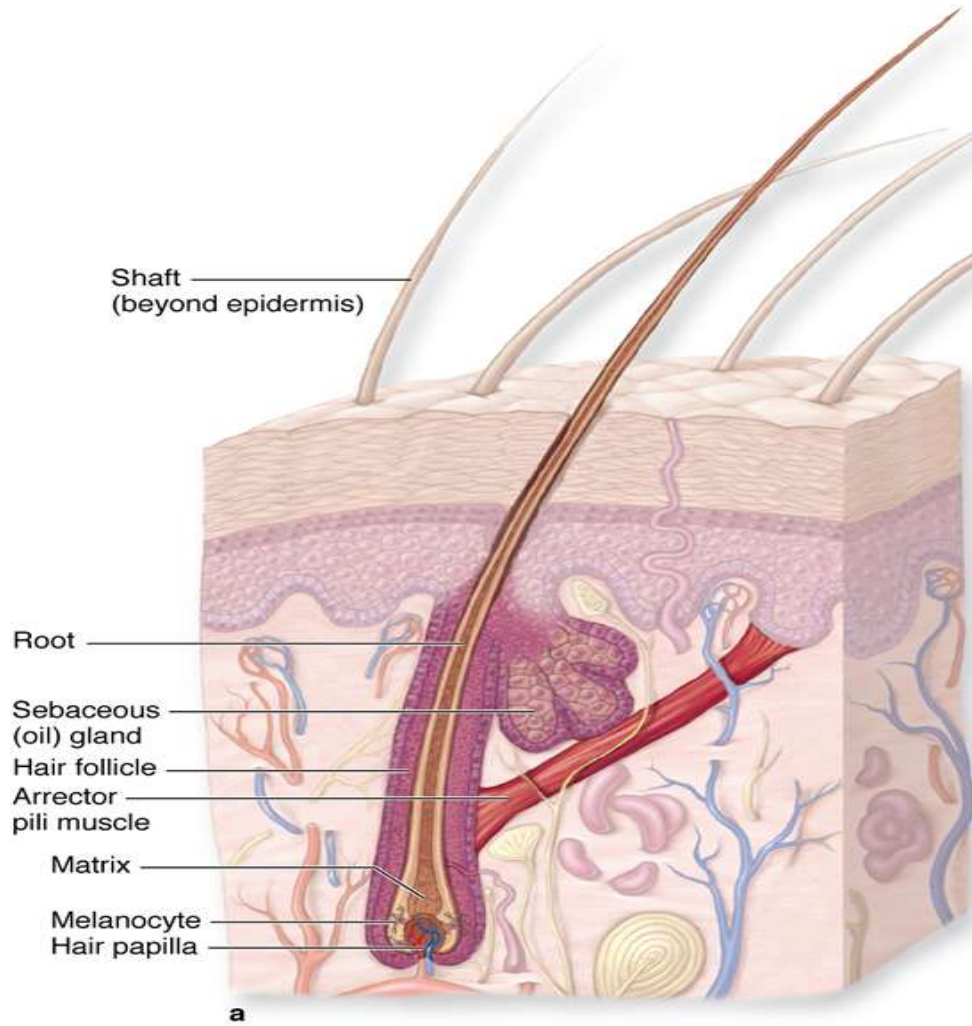
HAIR SHAFT

- **MEDULLA**- innermost layer of the Follicle, moderate Keratinisation Not distinguishable in fine hairs
- **CORTEX**- broad highly keratinised layer, Bulk of the Hair
- **CUTICLE**- Keratinisation to form hard cuticle, on the surface of hair, Overlapping keratin plates to prevent matting of hair
- **INTERNAL ROOT SHEATH**- lightly keratinised- **HUXLEY & HENLE LAYER**
- **EXTERNAL ROOT SHEATH**- no Hair formation, this layer separated from sheath of connective tissue surrounding the Follicle by thick specialised basement membrane= **GLASSY MEMBRANE**

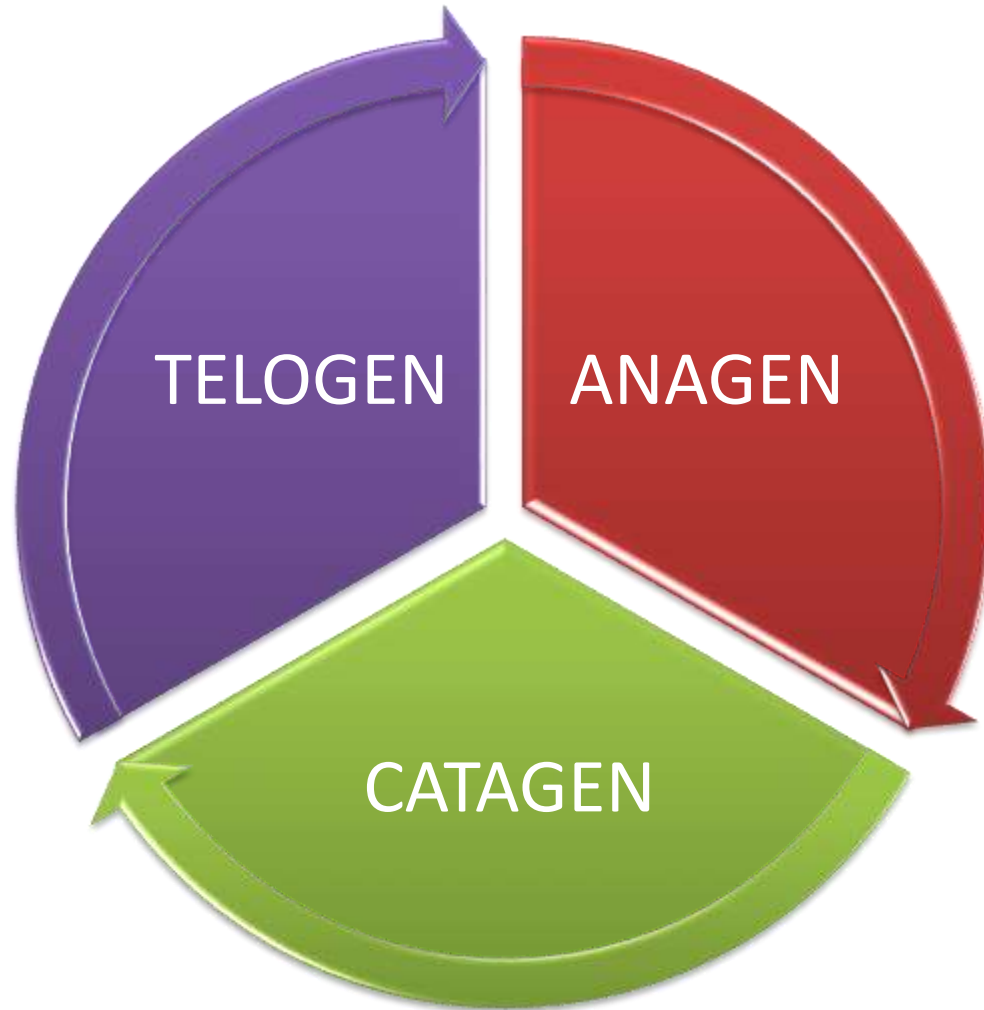








CYCLES OF HAIR GROWTH



Hair Growth in Scalp- 0.4mm/day

ANAGEN

- Growing phase
- 3 years in scalp

CATAGEN

- Involuting phase / regression
- 3 weeks in scalp

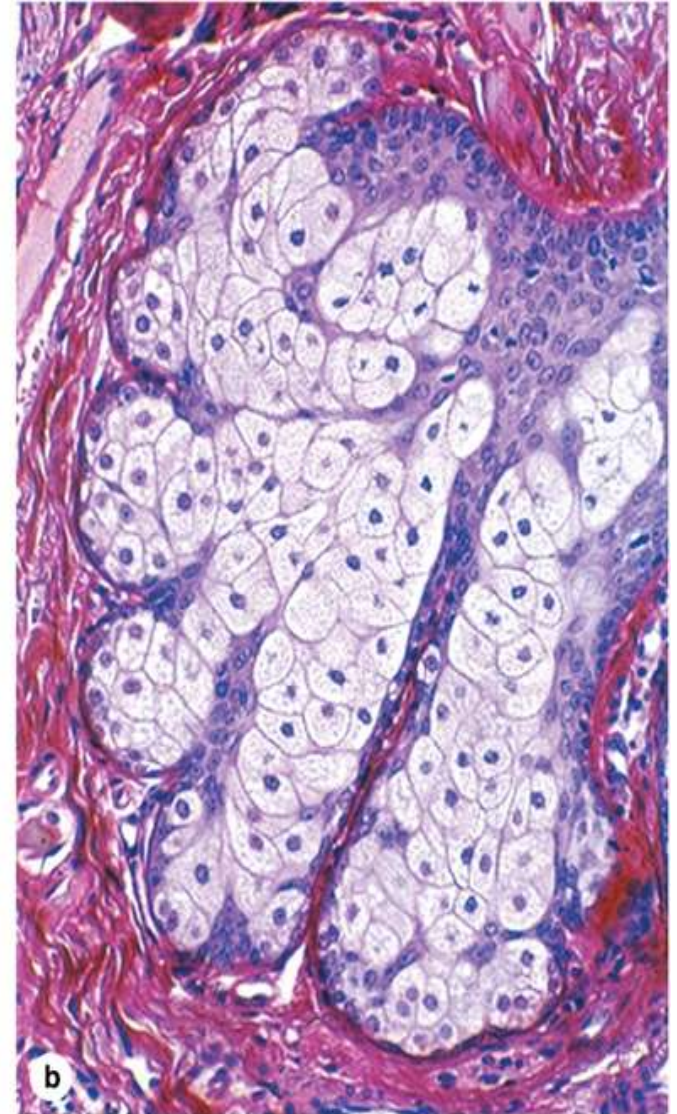
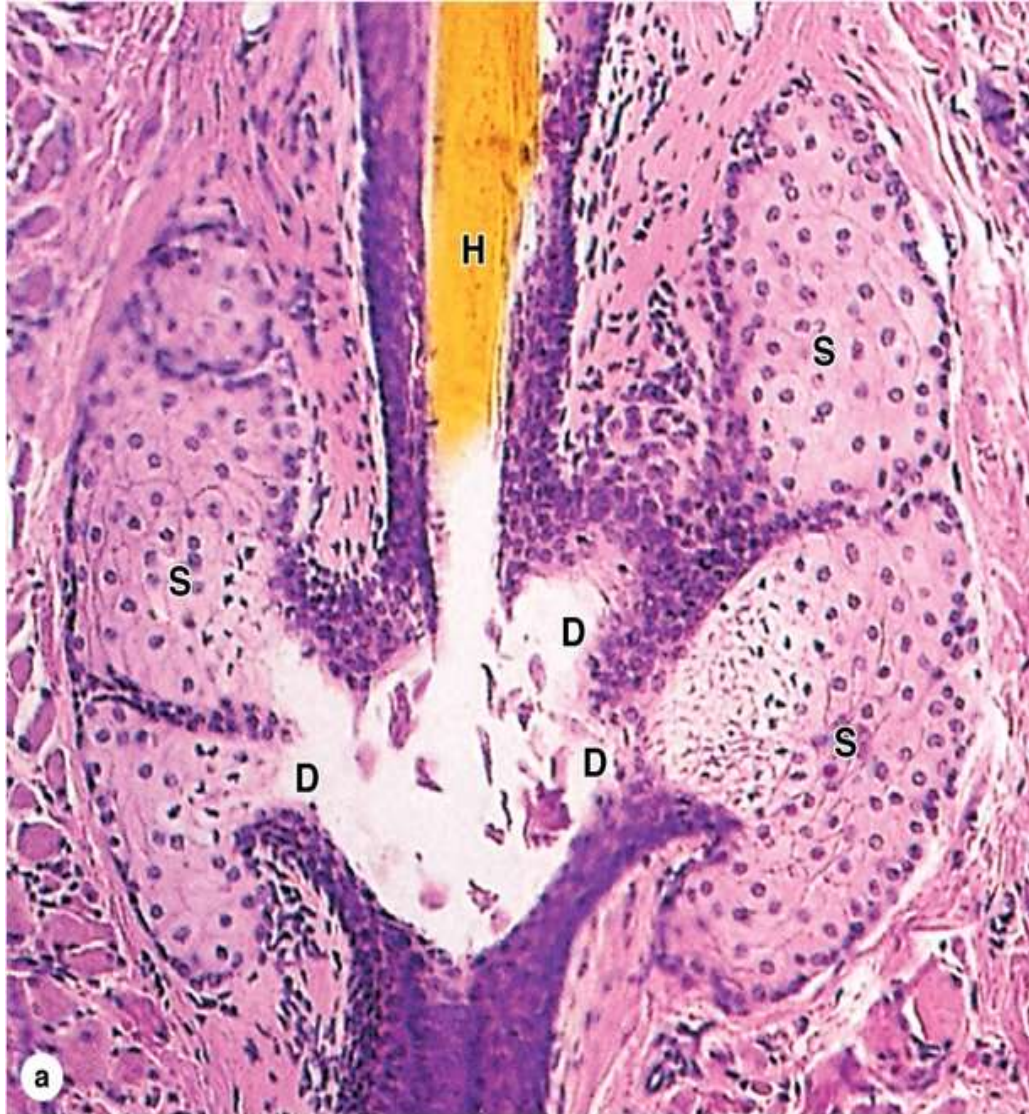TELOGEN

- Resting phase
- 3 months in scalp

SEBACEOUS GLAND

- Typical **multi vacuolated** appearance, centrally located nucleus
- Each Hair follicle is surrounded by one or more Sebaceous gland
- Excretory duct of the sebaceous glands opens into the **Infundibulum** of the Hair follicle.

SEBACEOUS GLAND



- Lipid content of acinar cells increases → distended cells degenerate → releases the **SEBUM= HOLOCRINE SECRETION**
- Cells lost are replaced by Mitosis in the basal layer of the acinus

PILOSEBACEOUS UNIT

Hair Follicle

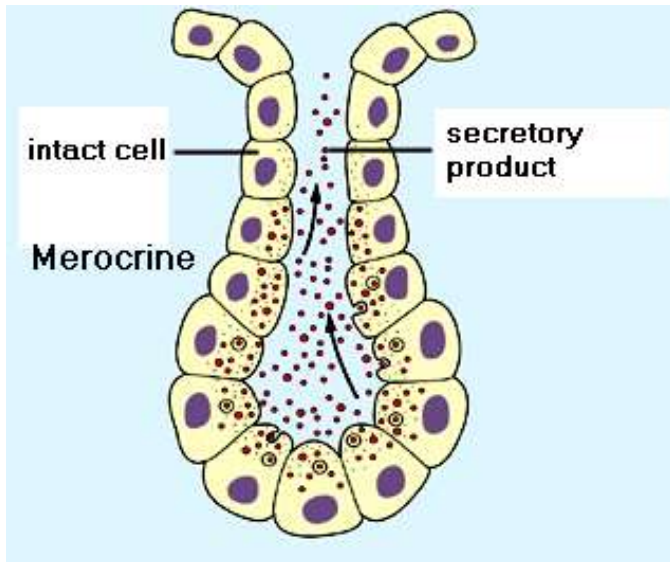
Arrector Pili muscle

Sebaceous gland

SWEAT GLANDS

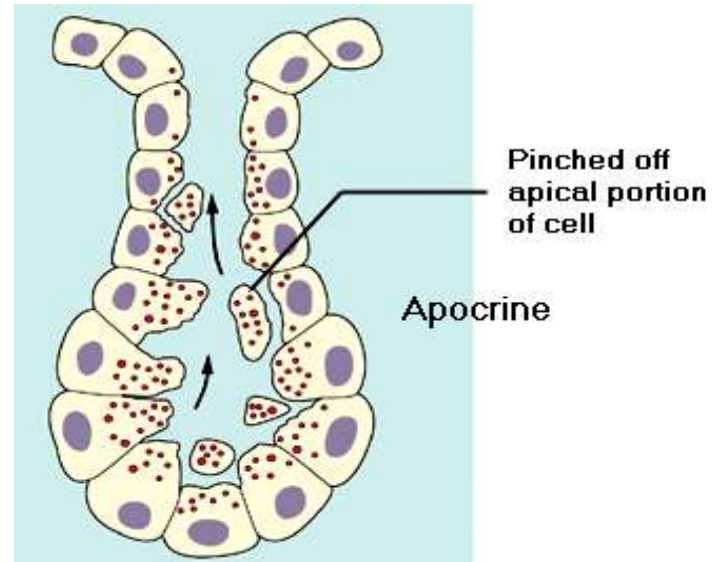
Eccrine sweat gland

- Empty directly onto skin surface
- Location: most all over body (esp. abundant on palms & soles)
- Clear, watery secretion
- Merocrine secretion

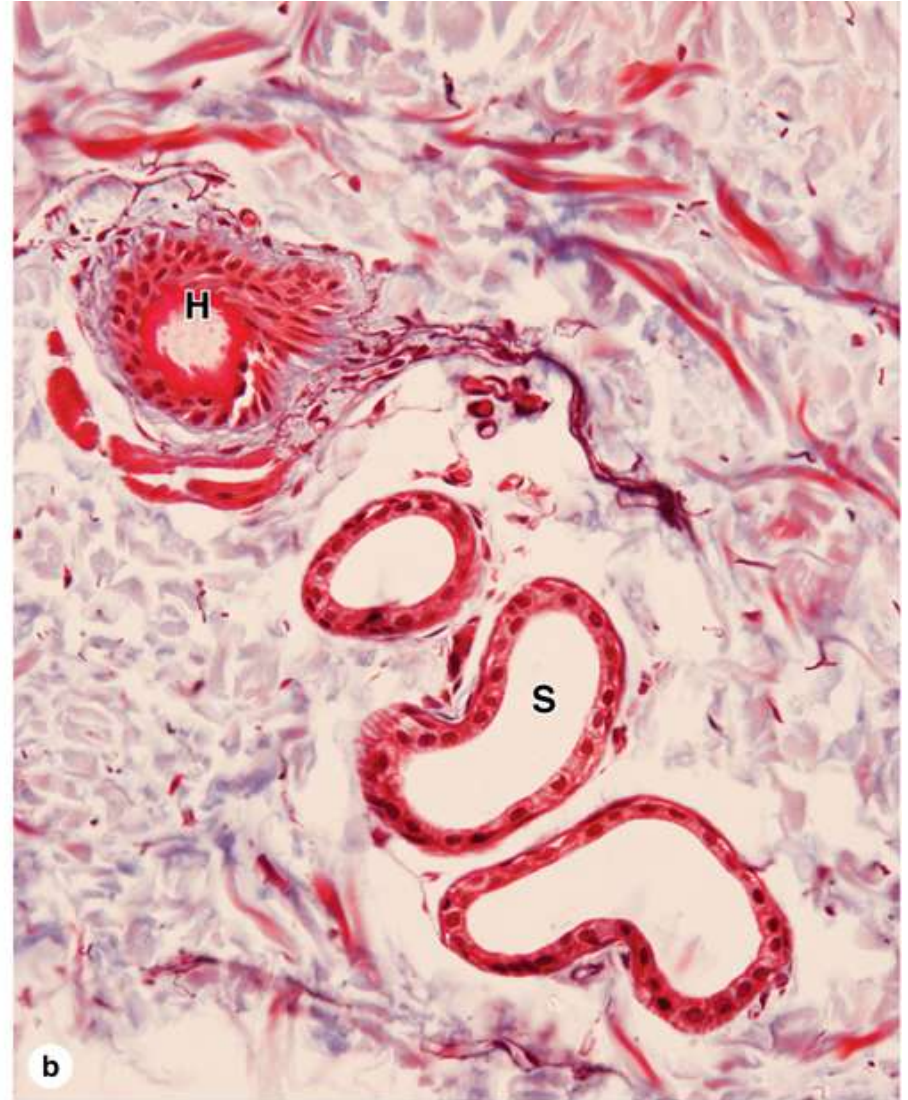
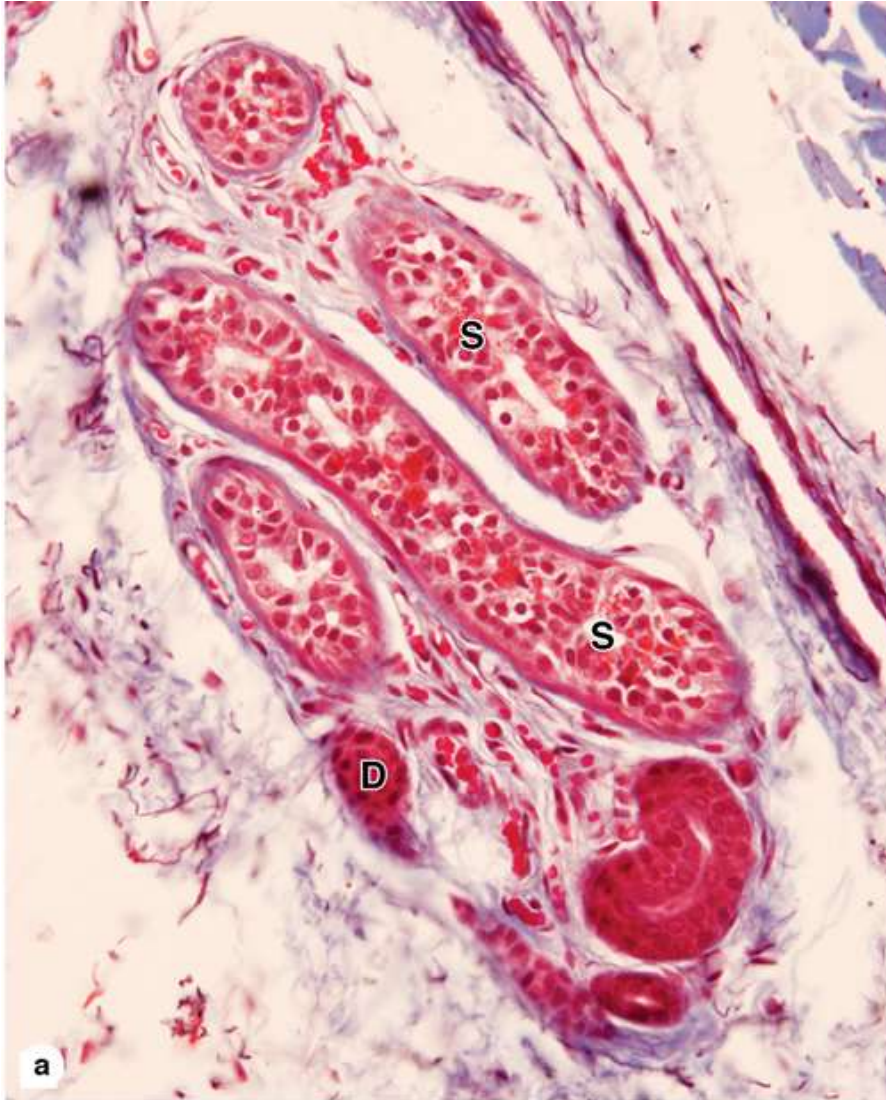


Apocrine sweat gland

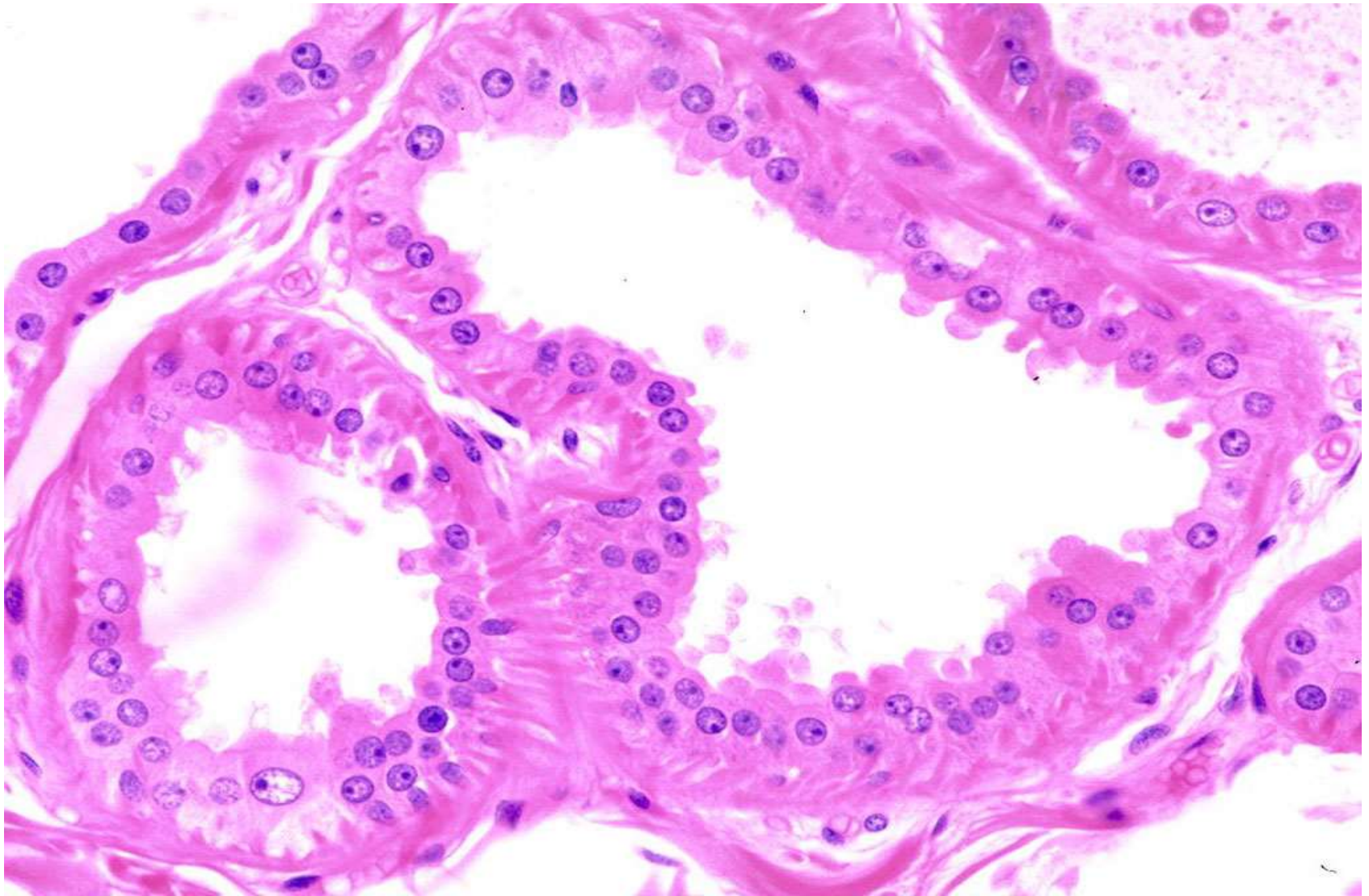
- Empty into hair follicle
- Location: armpits, groin, nipples
- Viscous, cloudy secretion
- Secretion begins at puberty and is stimulated during emotional distress



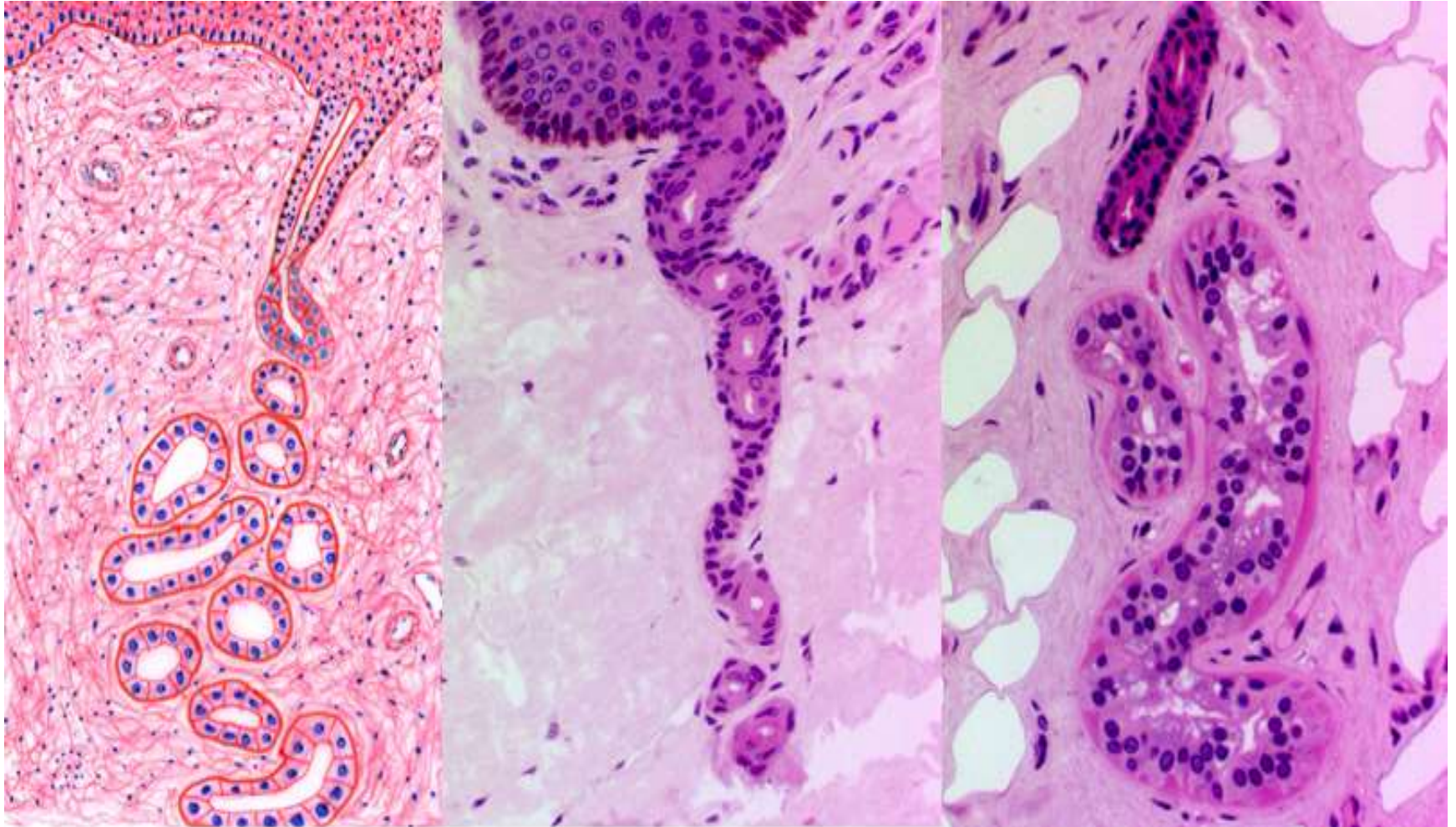
SWEAT GLAND



APOCRINE SWEAT GLAND



SWEAT GLAND



NAIL

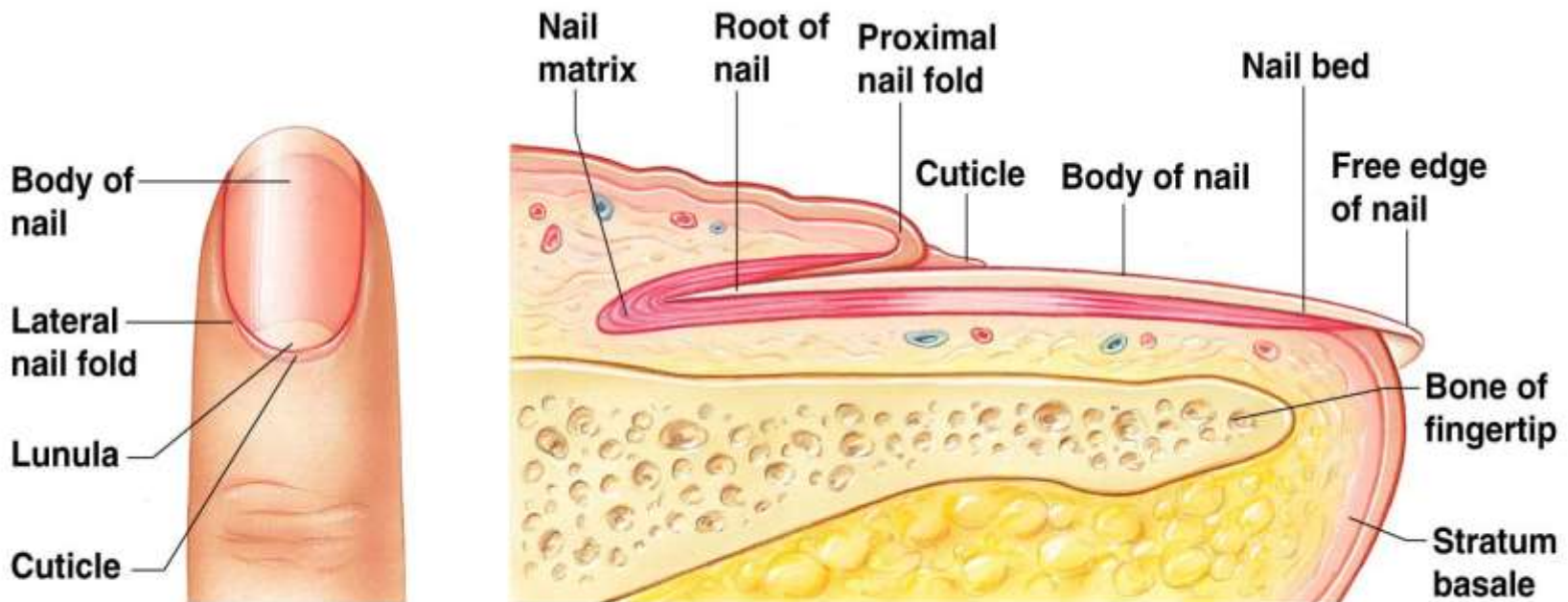
Scale-like modifications of the epidermis

Heavily keratinized

Stratum basale extends beneath the nail bed

Responsible for growth

Lack of pigment makes them colorless



(a) Surface view

(b) Longitudinal section of the distal part of a finger

References

- *Rosai and Ackerman's Surgical Pathology, Rosai -10th Edition-2011*
- *Lever Histopathology of Skin- 10th edition*
- *Wheater's Functional Histology- A Textbook & Colour Atlas- 5th Edition*
- *diFiore's Atlas of Histology with Functional correlation- 5th Edition*